



Research article

Prospective evaluation of fluciclovine (^{18}F) PET-CT and MRI in detection of recurrent prostate cancer in non-prostatectomy patients

Oladunni Akin-Akintayo^a, Funmilayo Tade^a, Pardeep Mittal^a, Courtney Moreno^a, Peter T. Nieh^b, Peter Rossi^b, Dattatraya Patil^b, Raghuveer Halkar^a, Baowei Fei^a, Viraj Master^b, Ashesh B. Jani^c, Hiroumi Kitajima^a, Adeboye O. Osunkoya^{b,d}, Claudia Ormenisan-Gherasim^{d,e}, Mark M. Goodman^a, David M. Schuster^{a,*}

^a Radiology and Imaging Sciences, Emory University, Atlanta, GA, United States

^b Urology, Emory University, Atlanta, GA, United States

^c Radiation Oncology, Emory University, Atlanta, GA, United States

^d Pathology and Laboratory Medicine, Emory University, Atlanta, GA, United States

^e Pathology, Brigham & Women's Hospital-Harvard Medical School, Boston, MA, United States

ARTICLE INFO

Keywords:

Fluciclovine
PET-CT
Multiparametric MRI
Prostate cancer

ABSTRACT

Purpose: To investigate the disease detection rate, diagnostic performance and interobserver agreement of fluciclovine (^{18}F) PET-CT and multiparametric magnetic resonance imaging (mpMR) in recurrent prostate cancer.

Methods: Twenty-four patients with biochemical failure after non-prostatectomy definitive therapy, 16/24 of whom had undergone brachytherapy, underwent fluciclovine PET-CT and mpMR with interpretation by expert readers blinded to patient history, PSA and other imaging results. Reference standard was established via a multidisciplinary truth panel utilizing histology and clinical follow-up (22.9 ± 10.5 months) and emphasizing biochemical control. The truth panel was blinded to investigative imaging results. Diagnostic performance and interobserver agreement (kappa) for the prostate and extraprostatic regions were calculated for each of 2 readers for PET-CT (P1 and P2) and 2 different readers for mpMR (M1 and M2).

Results: On a whole body basis, the detection rate for fluciclovine PET-CT was 94.7% (both readers), while it ranged from 31.6–36.8% for mpMR. Kappa for fluciclovine PET-CT was 0.90 in the prostate and 1.0 in the extraprostatic regions. For mpMR, kappa was 0.25 and 0.74, respectively.

In the prostate, 22/24 patients met the reference standard with 13 malignant and 9 benign results. Sensitivity, specificity and positive predictive value (PPV) were 100.0%, 11.1% and 61.9%, respectively for both PET readers. For mpMR readers, values ranged from 15.4–38.5% for sensitivity, 55.6–77.8% for specificity and 50.0–55.6% for PPV.

For extraprostatic disease determination, 18/24 patients met the reference standard. Sensitivity, specificity and PPV were 87.5%, 90.0% and 87.5%, respectively, for fluciclovine PET-CT, while for mpMR, sensitivity ranged from 50 to 75%, specificity 70–80% and PPV 57–75%.

Conclusion: The disease detection rate for fluciclovine PET-CT in non-prostatectomy patients with biochemical failure was 94.7% versus 31.6–36.8% for mpMR. For extraprostatic disease detection, fluciclovine PET-CT had overall better diagnostic performance than mpMR. For the treated prostate, fluciclovine PET-CT had high sensitivity though low specificity for disease detection, while mpMR had higher specificity, though low sensitivity. Interobserver agreement was also higher with fluciclovine PET-CT compared with mpMR.

1. Introduction

Management of recurrent prostate cancer poses a challenge since therapeutic options vary by the nature of the recurrence [1]. Salvage

local therapy is feasible for disease in the prostate, pelvic locoregional spread may be treated via external beam radiation, while more systemic disease is typically managed with androgen deprivation therapy.

Although conventional imaging techniques like computed

* Corresponding author at: Division of Nuclear Medicine and Molecular Imaging, Department of Radiology and Imaging Sciences, Emory University Hospital, 1364 Clifton Road, Atlanta, GA, United States.

E-mail address: dschust@emory.edu (D.M. Schuster).

<https://doi.org/10.1016/j.ejrad.2018.02.006>

Received 13 September 2017; Received in revised form 16 December 2017; Accepted 6 February 2018

0720-048X/© 2018 Elsevier B.V. All rights reserved.

tomography (CT), routine magnetic resonance imaging (MRI) and bone scintigraphy are commonly utilized in the evaluation of prostate cancer recurrence, their performance is suboptimal [2,3]. On the other hand, molecular imaging techniques for recurrent prostate cancer using choline, fluciclovine (¹⁸F) and newer PSMA-ligand positron emission tomography (PET) radiotracers are becoming increasingly recognized for their value [4–6].

Upregulation of amino acid transport has been described in prostate and other cancers [7]. One synthetic amino acid positron emission tomography (PET) radiotracer which exploits this principle for prostate cancer detection is *anti*-1-amino-3-[¹⁸F] fluorocyclobutane-1-carboxylic acid (FACBC, fluciclovine (¹⁸F)). Fluciclovine is transported mainly by the alanine-serine-cysteine transporter ASCT2 and to a lesser extent by system L amino acid transporter LAT1 [8]. Based upon favorable clinical data, fluciclovine was approved by the United States Food and Drug Administration (FDA) in May 2016 for imaging of suspected prostate cancer recurrence based on elevated blood prostate-specific antigen (PSA) levels following prior treatment [9–13].

We have previously described superior performance of fluciclovine PET-CT compared with CT and ¹¹¹In-capromab pentetide in the diagnosis of recurrent prostate cancer [11,14]. In the present study, our goal was to prospectively investigate the value and inter-observer variability of fluciclovine PET-CT in patients undergoing restaging for recurrent prostate cancer compared with multiparametric MR (mpMR), specifically in a non-prostatectomy population.

2. Materials and methods

2.1. Patient selection

Following institutional review board approval and informed consent, 25 patients with suspected recurrent prostate cancer who had earlier undergone non-prostatectomy definitive therapy were recruited into a prospective clinical trial. Inclusion criteria included suspicion of recurrent prostate cancer based on elevated PSA > nadir + 2 ng/ml with absolute PSA ≥ 4.0 ng/ml with any doubling time (DT) or with PSA 2.0–3.99 ng/ml with DT ≤ 10 months. The selection criteria were established to maximize the possibility of nodal spread to acquire tissue for a related histologic study. Additional enrollment criteria included > 1 year time lapse post-cryotherapy, external beam radiation, or high-intensity focused ultrasound (HiFU); or greater than 2 years for brachytherapy. A key exclusion criterion was bone scan findings characteristic for skeletal metastasis.

2.2. Imaging protocol

2.2.1. PET-CT

Fluciclovine preparation was completed as earlier reported [15,16]. Patients fasted for at least 4 h following which oral contrast was given and scanning completed on a GE Discovery MV690 PET-CT scanner (GE Healthcare, Wauwatosa, WI). An initial CT scan was completed for attenuation correction (approximately 100 mAs) and 370.0 ± 13.0 MBq (10.0 ± 0.35 mci) of fluciclovine was then intravenously infused via pump over two minutes, followed by a 3 min wait to allow for blood pool clearance. A 2.5 min/bed emission acquisition from pelvis to diaphragm (5–15 min) was performed and then immediately repeated (15.5–25.5 min). Images were reconstructed with iterative technique (VUE Point Fx; 3 iterations, 24 subsets. filter cutoff 6.4 mm, GE Healthcare, Wauwatosa, WI) and transferred to a MIMVista work station (MIM Software; Cleveland, OH) for interpretation.

2.2.2. MRI

Abdominopelvic MRI through the prostate was performed on a 1.5 T Aera MR scanner (Siemens Healthcare, Erlangen, Germany) using multiple Body 18 coils and the Spine 32 coil. MR parameters are outlined in Table 1. The number of slice groups was modified to account

Table 1 Whole-body mpMR parameters.

Sequence	AX T2 DWI WB	COR T2 HASTE AP	COR VIBE AP PRE/POST	COR T2 HASTE AP	SAG T2 PELVIS	AX T2 HASTE AP	AX TRUFISP AP	COR MRCP THICK	AX MRCP THIN	AX VIBE PROST DYN	AX T2FS HASTE AP	AX VIBE AP PRE/POST	AX SPACE PELVIS	AX T2 FSE PELVIS
Slice thickness/gap (mm)	5/0	6/1.2	4/0	6/1.2	6/1.2	6/1.2	6	50	4/0.8	3.5/0	6/1.2	3/0	1.5/0	3.5/0.2
FOV (cm)	50 × 50	50 × 45	50 × 50	45 × 36.6	30 × 30	45 × 36.6	45 × 36.6	30 × 30	39 × 39	26 × 26	45 × 36.6	42 × 34.1	28 × 28	20 × 20
Matrix	128 × 128	320 × 256	320 × 288	320 × 260	320 × 320	320 × 260	320 × 260	384 × 269	256 × 218	192 × 154	320 × 260	288 × 234	320 × 288	320 × 320
Averages	2 (b50), 5 (b800)	1	1	1	1	1	1	1	1	1	1	1	2	3
TR/TE/TI (ms)	13400/69/180	1200/91/0	4.03/1.83/0	1400/91/0	1400/102/0	1400/91/0	3.33/1.35/0	4500/746/0	1430/699/0	4.2/1.58/0	1400/94/0	4.06/1.9/0	1100/95/0	3720/101/0
b-values (s/mm ²)	50, 800	0:55	0:18	0:57	1:09	0:57	0:22	0:02	0:49	0:08	0:57	0:18	7:03	1:44
Acquisition time/slice group	5:22													
Slices	50	46	73	41	49	41	41	1	41	26	41	90	128	28
Slice groups	5	2	2	2	1	2	2	1	1	1	2	2	1	1
Bandwidth/pixel (Hz)	2298	700	405	710	710	505	505	150	250	300	710	405	600	200

AX = axial, COR = coronal, SAG = sagittal.

Table 2
Demographics Characteristics of Study Participants (n = 24).

Age (years):	
Mean \pm SD	70.8 \pm 5.7
Median (range)	70.5 (60–83)
Q1, Q3	66.5, 74.5
PSA (ng/ml):	
Mean \pm SD	8.5 \pm 6.1
Median (range)	6.8 (2.2–29.3)
Q1, Q3	4.9, 10.8
Original Gleason Score:	
Median (range)	7 (6–9)
Q1, Q3	6, 7
PET-MR Interval (days)	
Mean \pm SD	9.1 \pm 7.3
Median (range)	7.5 (0–29)
Q1, Q3	5.5, 12.5
Follow-up Interval after Study Imaging (months)	
Mean \pm SD	22.9 \pm 10.5
Median (range)	25.0 (1–43)
Q1, Q3	13.5, 29.3

for variation in patient height. To aid visualization, slice groups were composed and apparent diffusion coefficient (ADC) maps generated. Each b-value was displayed in an inverted grayscale, and rotating coronal and sagittal maximum-intensity projections (MIPs) were created.

2.3. Image interpretation

2.3.1. PET-CT

Interpretation was completed independently by two board certified nuclear medicine physicians (P1 with 20 years' and P2 with 30 years' experience) per previously reported dual-time point criteria [14,17]. Briefly, abnormal persistent uptake with at least moderate ($>$ marrow SUVmean at L3) activity between early and delayed sequences was considered malignant. Both interpreters were blinded to specific history, PSA and other imaging, including mpMRI. The seminal vesicles were evaluated as part of the prostate region.

2.3.2. mpMR

MR studies were interpreted by two board-certified abdominopelvic radiologists (M1 with 12 years' and M2 with 6 years' subspecialty body MR experience) on a Picture Archiving and Communication System (Centricity; GE Medical Systems, Milwaukee, WI), using standard institutional criteria taking into consideration anatomic morphology, perfusion analysis and DWI criteria. Low signal intensity on T2-weighted images, restricted diffusion on diffusion-weighted images, and arterial enhancement with delayed washout on dynamic contrast enhanced imaging were considered suspicious features. Lesions were regarded as malignant if they had at least one suspicious feature, and confidence was increased if there were a combination of abnormal features. As with fluciclovine, both interpreters were blinded to specific history, PSA and other imaging, and the seminal vesicles were evaluated as part of the prostate region.

2.3.3. Degree of confidence

The degree of confidence of interpretation of each reader was recorded using a 5-point Likert scale with "1" denoting definitely benign, "2" probably benign, "3" equivocal, "4" probably malignant, and "5" definitely malignant. The 5-point scale reflects the degree of confidence of the readers and is not intended to simulate the Prostate Imaging Reporting and Data System (PI-RADS) score. For the primary analysis, scores of 1–3 were considered negative. A secondary analysis where all equivocal interpretations were considered positive (scores 3–5) was also completed.

2.4. Reference standard

Following image interpretation, biopsy of the prostate and/or extraprostatic lesions identified on imaging were obtained as clinically appropriate. Clinical follow-up information, including PSA course was collected. Anonymized clinical summaries of each patient were presented to a multidisciplinary truth panel for the purpose of achieving consensus regarding the absence or presence of disease in the prostate and extraprostatic locations. The truth panel comprised two board certified urologists and one board certified radiation oncologist who were blinded to results of the study imaging (mpMR and fluciclovine PET-CT). To this end, results of histologic analysis were combined with clinical follow-up with an emphasis on PSA course and biochemical control after local salvage similar to previously reported consensus criteria [11,14,17]. Concordance between lesions identified on imaging and tissue obtained for histology were also ensured before assigning true positivity.

2.5. Statistical analyses

Positivity rates were calculated for fluciclovine PET-CT and mpMR for each reader on a whole-body analysis and for prostate and extraprostatic locations. Kappa was used to assess agreement between readers. Values greater than 0.9 were considered as almost perfect agreement while values 0.8–0.9, 0.6–0.79, 0.40–0.59, 0.21–0.39, and \leq 0.20 were regarded as strong, moderate, weak, minimal, and no agreement, respectively [18]. Diagnostic performance was computed in prostate and extra-prostate locations for each reader and confidence intervals were generated. Analysis was carried out using Statistical Analysis Software (SAS Version 9.4 SAS Institute Inc. Cary, NC) and Microsoft Excel 2010.

3. Results

3.1. Demographics

Twenty-five patients meeting the inclusion criteria were recruited. One patient was excluded from the final analysis because the mpMR scan was not performed for logistic reasons. All participants underwent mpMR within 0–29 (mean \pm SD = 9.1 \pm 7.3) days of undergoing fluciclovine PET-CT. Patients were followed up for an average \pm SD of 22.9 \pm 10.5 months. Demographic information is shown in Table 2.

3.2. Prior therapy

In total, 16/24 (66.7%) patients had prior brachytherapy either alone (3/16), in combination with one additional therapy (8/16), or as part of three or more treatment modalities (5/16). Of the remaining eight patients, 3/8 had prior radiotherapy alone, 2/8 had three or more treatment modalities not including brachytherapy and the remaining three had proton therapy (1/8), cryotherapy alone (1/8) and cryotherapy plus hormonal therapy (1/8).

3.3. Scan interpretation and confidence

In the prostate bed, PET readers P1 and P2 interpreted 24/25 studies as malignant (Likert 4 or 5), and 1/25 as benign (Likert 1 or 2). For mpMR, reader M1 interpreted 10/24 studies as malignant and 3/24 as benign; reader M2 interpreted 5/24 studies as malignant and 2/24 as benign. For PET readers P1 and P2, no patient was ranked "3" equivocal in the prostate on fluciclovine PET-CT, while 11/24 and 17/24 patients were considered equivocal by readers M1 and M2 respectively for mpMR.

In the extraprostatic region, PET reader P1 interpreted 8/25 studies as malignant, and 15/25 as benign; and reader P2 interpreted 8/25 studies as malignant, and 16/25 as benign. For mpMR, reader M1

interpreted 9/24 studies as malignant and 12/24 as benign; reader M2 interpreted 9/24 studies as malignant and 15/24 as benign. The number of equivocal interpretations in the extraprostatic region were 2/25 and 1/25 for readers P1 and P2, respectively; reader M1 had 3/24 equivocal extraprostatic interpretations and reader M2 had none.

Since one patient underwent PET but not mpMR, only 24 patients who underwent both exams were then included in the final analysis.

3.4. Inter-observer variability and kappa

The degree of agreement of interpretations was high for fluciclovine PET-CT with kappa (weighted) being 0.90 in the prostate and 1.0 in the extraprostatic region. There was greater variability with mpMR, with kappa values reflective of minimal agreement in the prostate (0.25) and moderate agreement in the extraprostatic regions (0.74).

3.5. Truth verification/reference standard

In the prostate, 22/24 patients had sufficient proof for the absence or presence of disease. The remaining two had no biopsy or sufficient follow-up information to reach a consensus about disease status. Per the reference standard, 13/22 were determined to have prostate disease, all confirmed by histology. The remaining 9/22 had benign histology results.

In the extraprostatic region, 18/24 patients had sufficient information to establish the presence or absence of disease. Consequently, 8/18 patients were deemed to have extraprostatic disease; 7 of whom had biopsy proof, while one had correlative imaging: bone-directed MRI and bone scan. Of the remaining 10/18 who were considered negative for extraprostatic disease, one had biopsy proof, in addition to clinical and PSA follow-up, while the consensus for the remaining 9 was based on clinical and PSA follow-up.

Since 2 patients had disease in both the prostate and extraprostatic regions, on a per patient basis, 19 patients met the reference standard for presence of disease, with 18/19 (94.7%) established histologically. On a regional basis, presence of disease was established via histologic confirmation in 13/13 (100%) patients in the prostate. For the extraprostatic region, presence of disease was established in 7/8 (87.5%) patients via histologic confirmation.

3.6. Disease detection by imaging

For readers P1 and P2, positive uptake was observed on fluciclovine PET-CT for all 13 patients who were determined to have prostate disease (histologic proof) (Table 3), resulting in a fluciclovine PET-CT disease detection rate of 100% (13/13) in the prostate. Multiparametric MRI had a detection rate of 38.5% (5/13) for reader M1 and 15.4% (2/13) for reader M2.

In the extraprostatic region, 8 patients were considered positive for disease. Of these, 7 had a positive fluciclovine PET (readers P1 and P2). Thus, in the extraprostatic region, fluciclovine PET-CT had a detection rate of 87.5% (7/8), while mpMR had detection rates of 50.0% (4/8) and 75.0% (6/8) for readers M1 and M2 respectively (Table 3).

Although 13 and 8 patients were positive for prostate and extraprostatic disease respectively, 2 patients had concurrent disease in both regions. Therefore, on a whole-body basis, 19 patients were determined to have disease. Of these, fluciclovine PET-CT detected disease in 18/19 with the resulting detection rate being 94.7%, while mpMR had detection rates of 36.8% (7/19) and 31.6% (6/19) for readers M1 and M2 respectively. There was no true positive lesion on mpMR that was not detected by fluciclovine PET-CT.

3.7. Diagnostic performance

3.7.1. Prostate

In total, 22 of the 24 patients met the reference standard for the

determination of disease status in the prostate (Table 3). Diagnostic performance for fluciclovine PET in the prostate was sensitivity of 100%, specificity of 11.1%, and PPV of 61.9%. For mpMR, sensitivity ranged from 15.4–38.5%, specificity: 55.6–77.8% and PPV: 50.0–55.6%. Full details of diagnostic performance are as shown in Table 3. Fig. 1 is an example of concordant interpretation in the prostate.

3.7.2. Extraprostatic

Eighteen of 24 patients met the reference standard for the determination of disease status in the extraprostatic region (Table 3). Diagnostic performance in the extraprostatic region for both PET readers was sensitivity of 87.5%, specificity of 90.0%, and PPV of 87.5%. For mpMR, sensitivity ranged from 50.0–75.0%, specificity: 70.0–80.0% and PPV: 57.1–75.0%. Details of diagnostic performance are shown in Table 3. The single false positive extraprostatic interpretation for fluciclovine was secondary to uptake in lymphoma, and was also false positive on mpMR. Fig. 2 is an example of discordant interpretation in the extraprostatic region.

3.8. Effect of equivocal interpretations on diagnostic performance

We also performed a secondary analysis of diagnostic performance considering score 3 interpretations as positive (Table 4).

Analyzing equivocal interpretations as positive improved the sensitivity of mpMR in the prostate bed for both readers M1 and M2 (38.5% to 92.3% for M1; 15.4% to 84.6% for M2) but reduced specificity for both readers (55.6% to 11.1% for M1; 77.8% to 0.0% for M2). There were no differences in diagnostic performance for PET readers with this analysis.

In the extraprostatic region, only the diagnostic performance for readers P2 and M1 changed with the alternative analysis. Sensitivity increased for reader M1 (50.0–62.5%) but specificity decreased (70.0% to 50.0%). For reader P2, sensitivity stayed the same; however, specificity reduced from 90.0 to 80.0%.

4. Discussion

We set out to examine the relative value and inter-observer variability of fluciclovine (^{18}F) PET-CT and multiparametric MR in the detection of recurrent prostate cancer in patients post non-prostatectomy local therapy.

We found that fluciclovine PET-CT detected disease as established via the standard of truth in 13/13 (100%) and 7/8 (87.5%) patients in the prostate and extraprostatic regions respectively. This compares to 2/13–5/13 (15.4–38.5%) and 4/8–6/8 (50.0–75.0%) patients in the prostate and extraprostatic regions for mpMR, respectively. On a whole body basis, the detection rates were 94.7% for fluciclovine and 31.6–36.8% for mpMR. All lesions detected on mpMR were detected by fluciclovine PET-CT.

On a regional basis, the sensitivity of fluciclovine PET-CT in the prostate was 100.0%, but at the expense of specificity of 11.1% with a PPV of 61.9%. The specificity of mpMR in the prostate was higher, ranging from 55.6–77.8% but at the expense of sensitivity ranging from 15.4–38.5% with PPV of 50.0–55.6%. For extraprostatic disease detection, the diagnostic performance of fluciclovine PET-CT was superior to that of mpMR with sensitivity 87.5% and specificity of 90.0% for fluciclovine PET-CT with PPV of 87.5%, versus 50.0–75.0% sensitivity and 70.0–80.0% specificity for mpMR, with PPV of 63.6–80.0%. Inter-observer agreement was higher for fluciclovine PET-CT with kappa of 0.90 and 1.0 in the prostate and the extraprostatic regions, respectively. Kappa for mpMR was 0.25 in the prostate and 0.74 in the extraprostatic regions.

Our findings are important because 20–30% of prostate cancer cases recur after primary therapy [19]. Identifying the location of recurrence informs therapy decisions. Critically, detection of extraprostatic disease

Table 3
Diagnostic Performance of Fluciclovine PET-CT vs Multiparametric MRI^a.

	P1	P2	M1	M2
Prostate (n = 22/24)				
True Positives	13	13	5	2
False Positives	8	8	4	2
True Negatives	1	1	5	7
False Negatives	0	0	8	11
Sensitivity (95% CI)	100.0(75.3, 100.0)	100.0 (75.3, 100.0)	38.5 (13.9, 68.4)	15.4 (1.9,45.5)
Specificity (95% CI)	11.1 (0.3, 48.3)	11.1 (0.3, 48.3)	55.6 (21.2, 86.3)	77.8 (40.0,97.2)
Accuracy (95% CI)	63.6 (40.7,82.8)	63.6 (40.7,82.8)	45.5 (24.4,67.8)	40.9 (20.7,63.7)
PPV ¹ (95% CI)	61.9 (38.4, 81.9)	61.9 (38.4, 81.9)	55.6 (21.2, 86.3)	50.0 (6.8,93.2)
NPV ² (95% CI)	100.0 (2.5, 100.0)	100.0 (2.5, 100.0)	38.5 (13.9, 68.4)	38.9 (17.3,64.3)
Extraprostatic (n = 18/24)				
True Positives	7	7	4	6
False Positives	1	1	3	2
True Negatives	9	9	7	8
False Negatives	1	1	4	2
Sensitivity (95% CI)	87.5 (47.4, 99.7)	87.5 (47.4, 99.7)	50.0 (15.7,84.3)	75.0 (34.9,96.8)
Specificity (95% CI)	90.0 (55.5, 99.8)	90.0 (55.5, 99.8)	70.0 (34.8,93.3)	80.0 (44.4,97.5)
Accuracy (95% CI)	88.9 (65.3,98.6)	88.9(65.3,98.6)	61.1 (35.8,82.7)	77.8 (52.4,93.6)
PPV ¹ (95% CI)	87.5 (47.4, 99.7)	87.5 (47.4, 99.7)	57.1 (18.4,90.1)	75.0 (34.9, 96.8)
NPV ² (95% CI)	90.0 (55.5, 99.8)	90.0 (55.5, 99.8)	63.6 (30.8,89.1)	80.0 (44.4,97.5)

P1 and P2 were PET-CT readers. M1 and M2 were mpMRI readers.

^a Equivocal interpretation analyzed as negative.

¹ PPV = Positive predictive value.

² NPV = Negative predictive value.

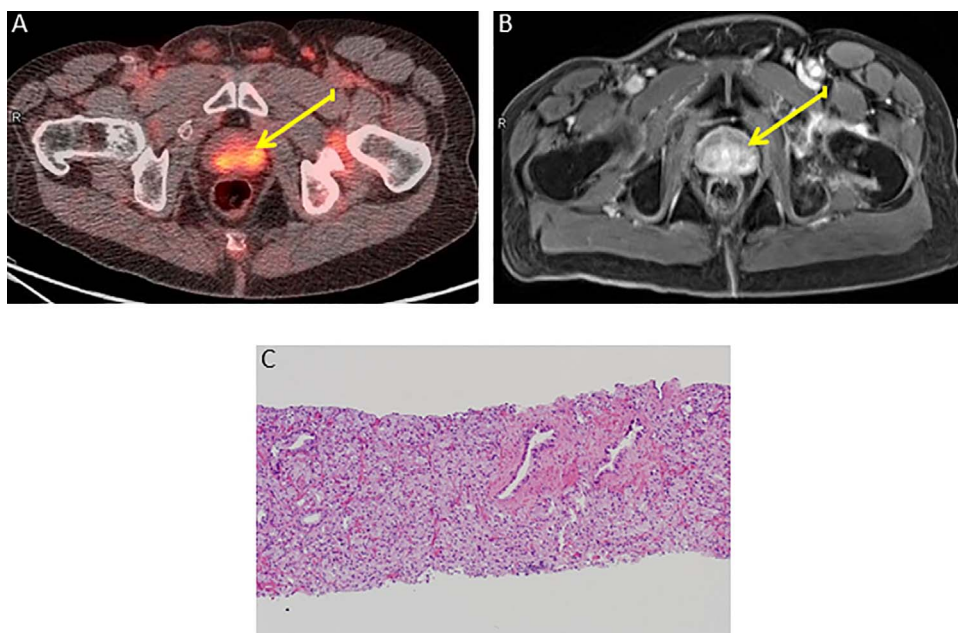


Fig. 1. Concordant interpretations on fluciclovine PET-CT and mpMR. 69-year old with elevated PSA post-radiotherapy (PSA 12.46 ng/ml) and positive prostate imaging (yellow arrows) on axial fluciclovine PET-CT (A) and mpMR (representative contrast enhanced sequence) (B). Biopsy specimen section shows Gleason score 4 + 3 = 7 (Grade Group 3) prostatic adenocarcinoma on hematoxylin and eosin staining at 10× magnification (C). (For interpretation of the references to colour in this figure legend, the reader is referred to the web version of this article.)

will alter therapy, often precluding local salvage therapy in favor of systemic androgen deprivation [1]. In this respect, the diagnostic performance of fluciclovine PET-CT was superior to that of mpMR, even in the alternative analysis in which equivocal lesions were considered positive, highlighting the utility of this radiotracer for more accurately restaging patients with recurrent prostate cancer, as we have previously reported [9,11,13,14].

In the prostate, though fluciclovine PET-CT had higher sensitivity at the expense of specificity for disease detection, mpMR demonstrated higher specificity at the expense of sensitivity. Interestingly, when MR indeterminate scores were analyzed as positive, diagnostic performance was similar to fluciclovine PET, with high sensitivity and low specificity. The high equivocation rate with mpMR in the prostate for both readers reflects the particular challenges that MR may have in this brachytherapy population due to lower lesion conspicuity in a

background of post-therapy decreased T2 signal intensity, and the presence of artifacts due to seed implants and distorted prostate anatomy [20,21].

Our results for mpMR appear discrepant from Tamada who reported a sensitivity of 77% and a specificity of 92% in a similar group of patients an average of 30 months after brachytherapy [22]. Yet, there is a paucity of data in this regard with most mpMR studies having relatively lower inclusion of brachytherapy patients [23,24]. Unlike for primary disease, there is no standardized PIRADS-like criteria for assessing and reporting mpMR examinations in recurrent prostate cancer [25].

For fluciclovine PET in the prostate, these findings are in keeping with our prior reports of high sensitivity with suboptimal specificity and moderate PPV [11,14]. While fluciclovine PET-CT should not be used alone to guide radiotherapy decisions in the prostate in non-prostatectomy patients, it may be useful to direct biopsy to the source of

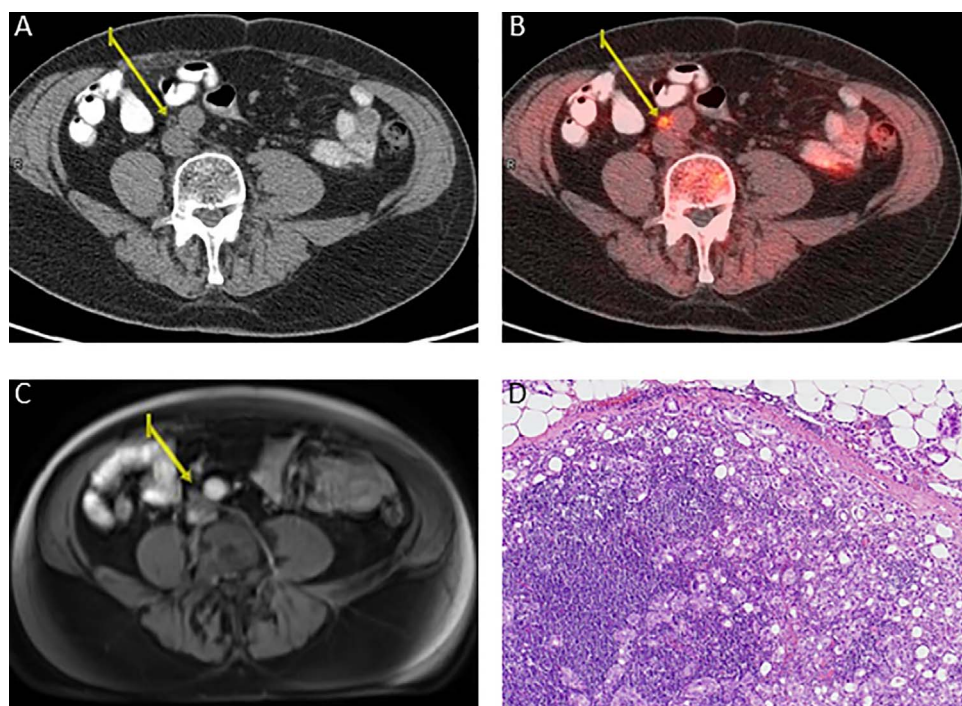


Fig. 2. Discordant interpretations on fluciclovine PET-CT and mpMR. 73-year old with elevated PSA post-brachytherapy and hormonal therapy (PSA 4.91 ng/ml). 0.7 × 0.3 cm aortocaval lymph node (yellow arrows) with a fatty hilum on axial CT (A) interpreted as malignant on axial fluciclovine PET-CT (B) and negative on mpMR (representative contrast enhanced sequence) (C). Laparoscopic biopsy hematoxylin and eosin stained lymph node section at 10× magnification shows metastatic prostate adenocarcinoma (D). (For interpretation of the references to colour in this figure legend, the reader is referred to the web version of this article.)

PSA elevation. Brachytherapy may also have exaggerated the effect of benign confounders such as inflammation and benign prostatic hyperplasia with fluciclovine [26,27] in the prostate. It is also possible that falsely negative biopsy sampling error occurred due to post-therapy prostate distortion and the presence of brachytherapy seeds.

Though results are not directly comparable due to differences in radiotracers, study design and reference standards, our findings also mirror the results of other studies comparing mpMR with molecular imaging techniques in the detection of recurrent prostate cancer. Kitajima reported better diagnostic performance of ¹¹C-choline PET-CT with mpMR in the detection of lymph node metastasis with higher interobserver agreement for ¹¹C-Choline PET-CT [28]. In that study, sensitivity for local recurrence was higher with mpMR, and specificity

was higher with ¹¹C-Choline PET-CT, however, the study was confined to patients who were post-prostatectomy.

On a whole body basis, the detection rate of fluciclovine PET-CT was 94.7% and 31.6–36.8% for mpMR. Our high detection rate, though encouraging is likely the result of purposely aiming for higher PSA levels in the study cohort. A recent study of ⁶⁸Ga-PSMA PET-CT detection efficacy in patients with biochemical recurrence post-radiotherapy reported results similar to ours for comparable PSA levels [29]. Evangelista, in a systematic review, described detection rates of approximately 95% for ⁶⁸Ga-PSMA PET-CT compared with 80% for both ¹⁸F-choline and ¹¹C-choline PET-CT at PSA levels > 2 ng/ml, but lower detection rates with all the radiotracers at PSA < 2 ng/ml [30]. Future studies may be designed to directly compare fluciclovine and PSMA PET-CT.

Table 4
Diagnostic Performance of Fluciclovine PET-CT vs Multiparametric MRI (Equivocal interpretation analyzed as positive).

	P1	P2	M1	M2
Prostate (n = 22/24)				
True Positives	13	13	12	11
False Positives	8	8	8	9
True Negatives	1	1	1	0
False Negatives	0	0	1	2
Sensitivity (95% CI)	100.0(75.3, 100.0)	100.0 (75.3, 100.0)	92.3 (64.0,99.8)	84.6 (54.6,98.1)
Specificity (95% CI)	11.1 (0.3, 48.3)	11.1 (0.3, 48.3)	11.1 (0.3,48.3)	0.00 (0.0,0.0)
Accuracy (95% CI)	63.6 (40.7,82.8)	63.6 (40.7,82.8)	59.1 (36.4,79.3)	50.0 (28.2,71.8)
PPV ¹ (95% CI)	61.9 (38.4, 81.9)	61.9 (38.4, 81.9)	60.0 (36.1,80.9)	55.0 (31.5,76.9)
NPV ² (95% CI)	100.0 (2.5, 100.0)	100.0 (2.5, 100.0)	50.0 (1.3,98.7)	0.00 (0.0,0.0)
Extraprostatic (n = 18/24)				
True Positives	7	7	5	6
False Positives	1	2	5	2
True Negatives	9	8	5	8
False Negatives	1	1	3	2
Sensitivity (95% CI)	87.5 (47.4,99.7)	87.5 (47.4,99.7)	62.5 (24.5,91.5)	75.0 (34.9,96.8)
Specificity (95% CI)	90.0 (55.5, 99.8)	80.0 (44.4,97.5)	50.0 (18.7,81.3)	80.0 (44.4,97.5)
Accuracy (95% CI)	88.9 (65.3,98.6)	83.3(58.6,96.4)	55.6 (30.8,78.5)	77.8 (52.4,93.6)
PPV ¹ (95% CI)	87.5 (47.4, 99.7)	77.8 (40.0,97.2)	50.0 (18.7,81.3)	75.0 (34.9, 96.8)
NPV ² (95% CI)	90.0 (55.5, 99.8)	88.9 (51.8, 99.7)	62.5 (24.5,91.5)	80.0 (44.4,97.5)

P1 and P2 were PET-CT readers. M1 and M2 were mpMRI readers.

¹ PPV = Positive predictive value.

² NPV = Negative predictive value.

The strengths of our study are the prospective trial design, multi-disciplinary truth panel blinded to research imaging, and high rate of histologic verification. Yet, our study is limited by relatively small sample size. Since patients with skeletal metastases on bone scan were excluded, no conclusions should be drawn about skeletal disease detection. The interpretation of mpMR was also based on institutional clinical standards and it is possible that stricter criteria may have improved diagnostic performance. We did not design the study to examine the relative value of individual MR sequences. It is possible that utilizing an endorectal coil, higher B value averages, or 3T MR may have improved diagnostic performance for mpMR. Finally, we accepted biopsy of the prostate as the reference standard though it is possible that there was sampling error since most of the biopsies were not image-guided. Despite these limitations, we believe these data provide a good foundation for future studies.

In conclusion, for disease detection in the non-prostatectomy prostate in a majority brachytherapy population, fluciclovine PET-CT has high sensitivity at the expense of specificity, while mpMR has a higher specificity at the expense of sensitivity. For the clinical concern of extraprostatic disease, fluciclovine PET-CT has better overall diagnostic performance compared with mpMR. As a practical approach, we believe that utilizing pelvic mpMR for its superior anatomic delineation and additional specificity in the prostate with the whole body staging abilities of fluciclovine PET-CT has the potential to harness the superior qualities of each modality to improve imaging of recurrent prostate cancer.

Conflicts of interest

Patents, Royalties and Licenses: Mark M. Goodman and Emory University are entitled to a royalty derived from the sale of products related to the research described in this manuscript. The terms of this arrangement have been reviewed and approved by Emory University in accordance with its conflict of interest policies.

Funding

This study was funded by National Institutes of Health (NIH P50 CA12830, R21CA176684, R01CA156775 and R01CA204254). Blue Earth Diagnostics Ltd. provided fluciclovine synthesis cassettes to Emory University for this project. Although not impacting this study, funding is or has been received from Blue Earth Diagnostics Ltd. and Nihon Medi-Physics Co., Ltd. through the Emory University Office of Sponsored Projects for other clinical trials using FACBC (fluciclovine).

Acknowledgements

We acknowledge the contributions of Leah Madge Bellamy, RN; Fenton Ingram, RT(R), CNMT, PET; Seraphinah Lawal, RT(R), CNMT, PET; Ronald Crowe, RPh, BCNP and the cyclotron/synthesis team from Emory University Center for Systems Imaging.

References

- J.L. Mohler, A.J. Armstrong, R.R. Bahnson, A.V. D'Amico, B.J. Davis, J.A. Eastham, C.A. Enke, T.A. Farrington, C.S. Higano, E.M. Horwitz, M. Hurwitz, C.J. Kane, M.H. Kawachi, M. Kuettel, R.J. Lee, J.J. Meeks, D.F. Penson, E.R. Plimack, J.M. Pow-Sang, D. Raben, S. Richey, M. Roach 3rd, S. Rosenfeld, E. Schaeffer, T.A. Skolarus, E.J. Small, G. Sonpavde, S. Srinivas, S.A. Strope, J. Tward, D.A. Shead, D.A. Freedman-Cass, Prostate cancer, version 1. 2016, *J. Natl. Compr. Cancer Netw.* 14 (1) (2016) 19–30.
- E.K. Outwater, J.L. Montilla-Soler, Imaging of prostate carcinoma, *Cancer Control: J. Moffitt Cancer Center* 20 (3) (2013) 161–176.
- T. Maurer, M. Eiber, S. Fanti, L. Budäus, V. Panebianco, Imaging for prostate cancer recurrence, *Eur. Urol. Focus* 2 (2) (2016) 139–150.
- G. Giovacchini, M. Picchio, A. Briganti, C. Cozzarini, V. Scattoni, A. Salonia, C. Landoni, L. Gianolli, N. Di Muzio, P. Rigatti, F. Montorsi, C. Messa, [11C]Choline positron emission tomography/computerized tomography to restage prostate cancer cases with biochemical failure after radical prostatectomy and no disease evidence on conventional imaging, *J. Urol.* 184 (3) (2010) 938–943.
- A. Afshar-Oromieh, C.M. Zechmann, A. Malcher, M. Eder, M. Eisenhut, H.G. Linhart, T. Holland-Letz, B.A. Hadaschik, F.L. Giesel, J. Debus, U. Haberkorn, Comparison of PET imaging with a (68)Ga-labelled PSMA ligand and (18)F-choline-based PET/CT for the diagnosis of recurrent prostate cancer, *Eur. J. Nucl. Med. Mol. Imaging* 41 (1) (2014) 11–20.
- H. Jadvar, Positron emission tomography in imaging evaluation of staging, restaging, treatment response, and prognosis in prostate cancer, *Abdom. Radiol. (New York)* 41 (5) (2016) 889–898.
- D.M. Schuster, C. Nanni, S. Fanti, Evaluation of prostate cancer with radiolabeled amino acid analogs, *J. Nucl. Med.* 57 (Suppl. 3) (2016) 61S–66S.
- H. Okudaira, S. Oka, M. Ono, T. Nakanishi, D.M. Schuster, M. Kobayashi, M.M. Goodman, I. Tamai, K. Kawai, Y. Shirakami, Accumulation of trans-1-amino-3-[(18)F]fluorocyclobutanecarboxylic acid in prostate cancer due to androgen-induced expression of amino acid transporters, *Mol. Imaging Biol.: MIB* 16 (6) (2014) 756–764.
- O.O. Akin-Akintayo, A.B. Jani, O. Odewole, F.I. Tade, P.T. Nieh, V.A. Master, L.M. Bellamy, R.K. Halkar, C. Zhang, Z. Chen, M.M. Goodman, D.M. Schuster, Change in salvage radiotherapy management based on guidance with FACBC (Fluciclovine) PET/CT in postprostatectomy recurrent prostate cancer, *Clin. Nucl. Med.* 42 (1) (2017) e22–e28.
- C. Nanni, L. Zanoni, C. Pultrone, R. Schiavina, E. Brunocilla, F. Lodi, C. Malizia, M. Ferrari, P. Rigatti, C. Fonti, G. Martorana, S. Fanti, (18)F-FACBC (anti-1-amino-3-(18)F-fluorocyclobutane-1-carboxylic acid) versus (11)C-choline PET/CT in prostate cancer relapse: results of a prospective trial, *Eur. J. Nucl. Med. Mol. Imaging* 43 (9) (2016) 1601–1610.
- O.A. Odewole, F.I. Tade, P.T. Nieh, B. Savir-Baruch, A.B. Jani, V.A. Master, P.J. Rossi, R.K. Halkar, A.O. Osunkoya, O. Akin-Akintayo, C. Zhang, Z. Chen, M.M. Goodman, D.M. Schuster, Recurrent prostate cancer detection with anti-3-[(18)F]FACBC PET/CT: comparison with CT, *Eur. J. Nucl. Med. Mol. Imaging* 43 (10) (2016) 1773–1783.
- B. Savir-Baruch, L. Zanoni, D.M. Schuster, Imaging of prostate cancer using fluciclovine, *PET Clinics* 12 (2) (2017) 145–157.
- T. Bach-Gansmo, C. Nanni, P.T. Nieh, L. Zanoni, T.V. Bogsrud, H. Sletten, K.A. Korsan, J. Kieboom, F.I. Tade, O. Odewole, A. Chau, P. Ward, M.M. Goodman, S. Fanti, D.M. Schuster, F. Willoch, Multisite experience of the safety, detection rate and diagnostic performance of fluciclovine (18F) positron emission tomography/computerized tomography imaging in the staging of biochemically recurrent prostate cancer, *J. Urol.* 197 (3 Pt. 1) (2017) 676–683.
- D.M. Schuster, P.T. Nieh, A.B. Jani, R. Amzat, F.D. Bowman, R.K. Halkar, V.A. Master, J.A. Nye, O.A. Odewole, A.O. Osunkoya, B. Savir-Baruch, P. Alaei-Taleghani, M.M. Goodman, Anti-3-[(18)F]FACBC positron emission tomography-computerized tomography and (111)In-capromab pentetide single photon emission computerized tomography-computerized tomography for recurrent prostate carcinoma: results of a prospective clinical trial, *J. Urol.* 191 (5) (2014) 1446–1453.
- J. McConathy, R.J. Voll, W. Yu, R.J. Crowe, M.M. Goodman, Improved synthesis of anti-[18F]FACBC: improved preparation of labeling precursor and automated radiosynthesis, *Appl. Radiat. Isot.* 58 (6) (2003) 657–666.
- J. McConathy, W. Yu, N. Jarkas, W. Seo, D.M. Schuster, M.M. Goodman, Radiohalogenated nonnatural amino acids as PET and SPECT tumor imaging agents, *Med. Res. Rev.* 32 (4) (2012) 868–905.
- D.M. Schuster, B. Savir-Baruch, P.T. Nieh, V.A. Master, R.K. Halkar, P.J. Rossi, M.M. Lewis, J.A. Nye, W. Yu, F.D. Bowman, M.M. Goodman, Detection of recurrent prostate carcinoma with anti-1-amino-3-(18)F-fluorocyclobutane-1-carboxylic acid PET/CT and (111)In-Capromab pentetide SPECT/CT, *Radiology* 259 (3) (2011) 852–861.
- M.L. McHugh, Interrater reliability: the kappa statistic, *Biochem. Med.* 22 (3) (2012) 276–282.
- S. Punnen, M.R. Cooperberg, A.V. D'Amico, P.I. Karakiewicz, J.W. Moul, H.I. Scher, T. Schlomm, S.J. Freedland, Management of biochemical recurrence after primary treatment of prostate cancer: a systematic review of the literature, *Eur. Urol.* 64 (6) (2013) 905–915.
- H.A. Vargas, C. Wassberg, O. Akin, H. Hricak, MR imaging of treated prostate cancer, *Radiology* 262 (1) (2012) 26–42.
- D.C. Oppenheimer, E.P. Weinberg, G.M. Hollenberg, S.P. Meyers, Multiparametric magnetic resonance imaging of recurrent prostate cancer, *J. Clin. Imaging Sci.* 6 (2016) 18.
- T. Tamada, T. Sone, Y. Jo, J. Hiratsuka, A. Higaki, H. Higashi, K. Ito, Locally recurrent prostate cancer after high-dose-rate brachytherapy: the value of diffusion-weighted imaging, dynamic contrast-enhanced MRI, and T2-weighted imaging in localizing tumors, *Am. J. Roentgenol.* 197 (2) (2011) 408–414.
- O. Akin, D. Gultekin, H.A. Vargas, J. Zheng, C. Moskowitz, X. Pei, D. Sperling, L. Schwartz, H. Hricak, M. Zelefsky, Incremental value of diffusion weighted and dynamic contrast enhanced MRI in the detection of locally recurrent prostate cancer after radiation treatment: preliminary results, *Eur. Radiol.* 21 (9) (2011) 1970–1978.
- S. Kanoun, P. Walker, J.-M. Vrigneaud, E. Depardon, V. Barbier, O. Humbert, M. Moulin, G. Créhanche, L. Cormier, R. Loffroy, F. Brunotte, A. Cochet, 18F-Choline PET/CT and multiparametric MRI for the detection of early local recurrence of prostate cancer initially treated by radiotherapy: comparison with systematic 3D-transperineal mapping biopsy, *Int. J. Radiat. Oncol. Biol. Phys.* 97 (5) (2017) 986–994.
- J.C. Weinreb, J.O. Barentsz, P.L. Choyke, F. Cornud, M.A. Haider, K.J. Macura, PI-RADS prostate imaging – reporting and data system: 2015 version 2, *Eur. Urol.* 69 (2016).
- D.M. Schuster, P.A. Taleghani, P.T. Nieh, V.A. Master, R. Amzat, B. Savir-Baruch,

- R.K. Halkar, T. Fox, A.O. Osunkoya, C.S. Moreno, J.A. Nye, W. Yu, B. Fei, Z. Wang, Z. Chen, M.M. Goodman, Characterization of primary prostate carcinoma by anti-1-amino-2-[(18)F] – fluorocyclobutane-1-carboxylic acid (anti-3-[(18)F] FACBC) uptake, *Am. J. Nucl. Med. Mol. Imaging* 3 (1) (2013) 85–96.
- [27] B. Turkbey, E. Mena, J. Shih, P.A. Pinto, M.J. Merino, M.L. Lindenberg, M. Bernardo, Y.L. McKinney, S. Adler, R. Owenius, P.L. Choyke, K.A. Kurdziel, Localized prostate cancer detection with (18)F FACBC PET/CT: comparison with MR imaging and histopathologic analysis, *Radiology* 270 (3) (2014) 849–856.
- [28] K. Kitajima, R.C. Murphy, M.A. Nathan, A.T. Froemming, C.E. Hagen, N. Takahashi, A. Kawashima, Detection of recurrent prostate cancer after radical prostatectomy: comparison of 11C-choline PET/CT with pelvic multiparametric MR imaging with endorectal coil, *J. Nucl. Med.* 55 (2) (2014) 223–232.
- [29] I. Einspieler, I. Rauscher, C. Duwel, M. Kronke, C. Rischpler, G. Habl, S. Dewes, A. Ott, H.J. Wester, M. Schwaiger, T. Maurer, M. Eiber, Detection efficacy of hybrid 68Ga-PSMA ligand PET/CT in prostate cancer patients with biochemical recurrence after primary radiation therapy defined by phoenix criteria, *Journal of nuclear medicine: official publication, Soc. Nucl. Med.* 58 (7) (2017) 1081–1087.
- [30] L. Evangelista, M.G. Bonavina, E. Bombardieri, Clinical results and economic considerations of 68Ga-PSMA and radiolabeled choline in prostate cancer, *Nucl. Med. Biol.* 50 (2017) 47–49.