

PRINCIPLES USED IN EVALUATING BRAIN FUNCTIONS WITH PSYCHOLOGICAL TESTS
AT THE NEUROPSYCHOLOGY LABORATORY, INDIANA UNIVERSITY MEDICAL CENTER

Ralph M. Reitan

Professor of Psychology, (Neurology)

(January, 1959)

During the last seven and one-half years a research program aimed toward establishment of principles for use in evaluating brain functions in human beings has been conducted in the Neuropsychology Laboratory at the Indiana University Medical Center. A standard battery of psychological tests has been administered to each of about 2,000 patients. The battery requires about one to one and one-half days for complete administration and yields a large number of test results for each patient. The tests all are administered individually.

An unusual opportunity has been available for relating the test results to neurological and neurosurgical descriptions of the brain since a special effort has been made by the staff neurologists and neurosurgeons to provide complete and accurate neurological criteria for use in the research. A number of studies have been completed yielding highly significant results that permit statements of a number of principles. The following statements refer to the general question of the presence or absence of brain damage.

1. The Halstead Impairment Index serves as a valid and reliable basis for inferring the presence or absence of brain damage in individual subjects (1).

In a group of 50 patients with brain damage and 50 control subjects

with no evidence of brain damage (matched in pairs for color, sex, age, and education) none of the brain-damaged persons obtained better Impairment Indexes than their matched controls. Using the best cut-off point in the two raw score distributions, 4% of the brain-damaged group were misclassified and 14% of the controls were misclassified.

2. The Halstead Category Test serves as a fairly valid indicator for differentiating patients with and without brain damage (1).

In this same study 16% of the brain-damaged subjects were misclassified and 18% of the controls.

3. The Localization component of the Halstead Tactual Performance Test also serves fairly well for the general question of brain damage or no brain damage (1).

Sixteen percent of the brain-damaged subjects and 20% of the controls were misclassified.

4. Two measures based on critical flicker frequency showed no significant differences and the Memory component of the Time Sense Test yielded a difference significant only at the .02 level. The remaining tests, however, showed highly significant differences between the groups with and without brain damage (1).

One cannot predict in individual instances which test or tests may be of crucial help. While the Impairment Index, Category Test, and Localization component of the Tactual Performance Test are generally the most helpful measures, not uncommonly does one of the other tests turn out to be particularly important for individual patients.

5. Either Part B of the Trail Making Test or the total of Part A plus Part B of this test differentiates patients with and without brain damage fairly well (2,3).

The first of these studies compared small groups of subjects (N=27) who were arranged in pairs matched for color, sex, age, and education. The results indicated that a total of approximately 17% of the patients were misclassified. The proportions of misclassified patients were nearly the same in both groups. The second study was based on 84 control subjects and 200 brain-damaged subjects. The results indicated a total misclassification of 14.8% of the subjects. Among the controls there were 16.7% misclassified and among the brain-damaged subjects, 14.0%. The cut-off point best differentiating the groups was the same in both studies.

6. The Halstead Impairment Index differentiates groups of subjects with and without brain damage better than do any of a number of measures from the Wechsler-Bellevue Scale (Verbal IQ, Performance IQ, Full-Scale IQ, "Hold" tests, "Don't Hold" tests, and the Wechsler Mental Deterioration Ratio) at extreme levels of statistical significance (4).

A method was devised for direct comparison of the extent of accurate discrimination of patients with and without brain damage who had been tested both with Halstead's tests and the Wechsler-Bellevue Scale. The Halstead Impairment Index differentiated the groups better than did any of the Wechsler measures mentioned above ($p < .001$ in each comparison).

7. Dysphasic symptoms, when present, provide a valid basis for inferring the presence of brain damage (5).

An aphasia screening examination was administered to 148 subjects with brain damage and 79 subjects without brain damage. This examination requires only about 15 to 20 minutes for administration, but a considerable amount of experience is necessary for the interpreter to be able to draw

valid and reliable conclusions regarding the presence or absence of positive findings. Comparison of the groups indicated the following results:

Cases Showing <u>X</u> No. of Symptoms: X =	<u>0</u>	<u>1</u>	<u>2</u>	<u>3</u>	<u>4</u>
Proportion of Group with Brain Damage:	.20	.38	.86	.87	1.00

The proportion of brain-damaged cases was .20 even in the group showing no positive symptoms on this test, but where two or more symptoms were found the proportion of brain-damaged cases was .86 or greater. Although a number of the brain-damaged persons showed no positive dysphasic symptoms (17%), a study of the groups shows that when such symptoms occur in a brain-damaged patient there is frequently more than one symptom (83% of the time). Dyscalculia, dysgraphia, spelling dyspraxia, or construction dyspraxia occurred commonly. At least one of these was always present when four or more symptoms were shown by any patient.

Several studies have yielded results differentiating patients with lesions of the left hemisphere from patients with lesions of the right hemisphere at acceptable levels of statistical significance.

8. The presence of aphasic symptoms provides a valid basis for the inference that the left cerebral hemisphere is damaged (6).

Groups were composed of 58 patients with damage of the right cerebral hemisphere and 47 patients with damage of the left cerebral hemisphere. Aphasia examinations had been administered to each patient and judgments recorded with respect to the presence or absence of specific aphasic

symptoms. Serious difficulties in naming, reading, spelling, writing, and calculating were commonly encountered in the group with damage of the left cerebral hemisphere but were far less frequent in the group with damage of the right cerebral hemisphere. For example, the percentage of patients with lesions of the left or right hemisphere, respectively, showing certain symptoms were as follows: dysnomia, 53% and 0%; dyslexia, 47% and 0%; spelling dyspraxia, 49% and 7%; dysgraphia, 51% and 2%; and dyscalculia, 55% and 14%.

9. The frequency of construction dyspraxia (as shown in difficulty in copying accurately common spatial configurations) is much greater in patients with damage of the right cerebral hemisphere than in patients with damage of the left cerebral hemisphere (6).

In the evaluation of aphasic symptomatology the test used requires the subject to copy several simple configurations such as a square, cross, and triangle and also copy a line drawing of a key. The results indicated that patients with lesions of the right hemisphere frequently show gross distortion of these spatial configurations. Distortion of the Greek cross occurs frequently and is easily recognized because of the regular spatial characteristics of its form. Sixty-four percent of the patients with lesions of the right hemisphere gave evidence of construction dyspraxia and 15% of the patients with lesions of the left hemisphere showed this symptom.

10. A number of additional findings of disturbances in simple perceptive abilities using the sensory modalities of touch, hearing, and vision often prove to be of valuable aid in lateralizing brain lesions (6).

Using the groups mentioned in Principle 8, the following proportions

of patients with positive symptoms occurred:

	<u>Left Cerebral Lesions</u>	<u>Right Cerebral Lesions</u>
Dystereognosis - right	31	2
Dystereognosis - left	2	32
<hr/>		
Finger dysgnosia - right	37	0
Finger dysgnosia - left	0	28
<hr/>		
Tactile suppression - right	16	0
Tactile suppression - left	2	22
<hr/>		
Auditory suppression - right	5	0
Auditory suppression - left	2	14
<hr/>		
Visual suppression - right	2	0
Visual suppression - left	0	17
<hr/>		

Several studies relating to lateralization of psychological functions in the brain have been done using results obtained with the Wechsler-Bellevue Scale.

11. The verbal weighted score total on the Wechsler-Bellevue Scale is rather consistently less than the performance weighted score total in patients with lesions of the left hemisphere and the converse relationship occurs consistently for patients with lesions of the right cerebral hemisphere (7).

These results were obtained in a study of 14 patients with lesions of the left cerebral hemisphere, 17 patients with right-sided cerebral lesions, and 31 patients with diffuse lesions involving both hemispheres. Thirteen of the 14 patients with left-sided lesions had lower verbal than

performance weighted score totals. Fifteen of the 17 patients with right-sided lesions, however, had a higher verbal than performance total. The patients with diffuse brain damage were nearly evenly distributed with respect to those having higher verbal or performance totals. The mean verbal subtest scores were in each instance higher for the right-sided group than the left-sided group. On the performance subtests the situation was reversed, the left-sided group having the higher means in each instance. The levels on the verbal and performance subtests for the group with diffuse involvement showed scarcely any difference.

12. When using lateralization of electroencephalographic disturbances as the criterion for composition of groups, exactly the same relationships between verbal and performance parts of the Wechsler-Bellevue were obtained as in the previous finding (8).

In this study Kløve used 37 patients with EEG disturbances of the left hemisphere, 42 with EEG disturbances of the right hemisphere, 45 with generalized EEG disturbances of both hemispheres, and 61 patients with established brain damage but normal EEG tracings. The same relationships between verbal and performance subtests were obtained as in the preceding study. The group with left cerebral EEG disturbances had lower means on each verbal subtest than did the group with right cerebral EEG abnormalities. The reverse relationship of these groups occurred on each of the performance subtests. The group with generalized EEG disturbances of both hemispheres occupied a middle position on both the verbal and performance scales, with little difference in level of performance. The fourth group, with brain damage but normal EEG results, also showed little difference in level on the verbal and performance scales, but had the

highest means in any of the groups on nine of the ten subtests used.

13. Distortion of the spatial configuration in attempting to copy a Greek cross is associated with lowered scores on the performance subtests of the Wechsler-Bellevue Scale, dysphasia is associated with lowered scores on the verbal subtests, and the presence of both of these behavioral deficits is associated with lowered scores on both the verbal and performance scales (9).

Kløve and Reitan studied the Wechsler-Bellevue results on 36 patients who were unable to copy a Greek cross without distorting the spatial configuration, 22 patients who showed evidence of dysphasia upon careful examination, and 13 patients who had both of these behavioral deficits. The results of this study were very similar to the previous two studies. The patients who had difficulty copying the Greek cross did poorly on the performance part of the Wechsler-Bellevue Scale, the dysphasic patients did poorly on the verbal part, and the group with both difficulties had low scores on both parts. The criteria of dysphasia or defective ability to copy a Greek cross were selected for composition of the groups because (a) they are usually easily elicited behavioral defects, (b) they both occur rather frequently (patients with each difficulty constitute 20 to 30% of the patients examined in the Indiana Neuropsychology Laboratory), and (c) numerous publications have related dysphasia to dysfunction of the left hemisphere and of difficulty in organizing and effecting spatial relationships to lesions of the right hemisphere.

14. Patients with damage of the left cerebral hemisphere have difficulty with Part B as compared with Part A of the Trail Making Test, whereas patients with right cerebral lesions perform significantly better on Part B with relation to Part A (10).

In a study by Reitan and Tarshes of 44 patients with damage of the left cerebral hemisphere, 50 patients with right hemisphere damage, and 46 patients with diffuse cerebral damage, a prediction was made that patients with left cerebral lesions would perform more poorly on Part B with relation to Part A than patients with damage to the right cerebral hemisphere. We anticipated that the limiting factor for patients with lesions of the left cerebral hemisphere would be their impaired ability to perceive and use the symbolic material represented in the content of the test. Consequently, Part B of the test involving both numbers and letters would represent a much more difficult task for them than Part A which involves only numbers. In patients with lesions of the right hemisphere, however, we postulated that the limiting factor would be the ability to comprehend the spatial configuration of the stimulus material. Since the stimulus material in both Parts A and B is distributed approximately equally in space, we expected that the difference in performance between the two parts of the test would be less for this group than for the patients with damage of the left hemisphere. Significant mean differences in comparative performance on Parts A and B occurred in comparing the groups with lateralized brain lesions ($p < .001$), with the differences falling in the predicted direction. The best cut-off point in the distributions of difference scores divided 72% of the group with right hemisphere damage from 75% of the group with damage of the left hemisphere. The group with diffuse cerebral damage was exactly equally divided on either side of this cut-off point.

15. Comparison of the mean differences in time required for completion of the Tactual Performance Test with the right and left hands in

patients with lateralized brain lesions indicates that patients with left cerebral lesions take a comparatively longer time with the right hand and patients with right cerebral lesions take a comparatively longer time with the left hand (11).

Eighteen patients with left cerebral lesions were compared with 30 patients having lesions of the right cerebral hemisphere on the relative speed of performing the task required by the Tactual Performance Test with the right and left hands. The groups were of approximately the same mean age and education. The task was done first with the right hand and then, without advance notification, the patient was asked to do exactly the same task with the left hand. Only right-handed patients were used. Patients with lesions of the left cerebral hemisphere required a mean of 8.86 minutes longer with the right hand than with the left hand. Conversely, patients with damage of the right cerebral hemisphere required a mean of 4.81 minutes longer with the left hand than with the right hand. This difference between groups was statistically significant ($t= 6.73$; $p < .001$). A cut-off point that best differentiated the groups was determined for use in a subsequent cross-validation study.

16. Patients with lateralized brain lesions were compared with respect to differences in finger tapping speed of the right and left index fingers. In the group with left cerebral lesions the right index finger was comparatively slow and in the group with right cerebral lesions the left index finger was comparatively slow (11).

Groups of 18 patients with left cerebral lesions and 23 patients with right cerebral lesions were compared. These groups overlapped considerably with those used in establishing Principle 15. Only right-handed subjects

were used. The mean of five ten-second trials was obtained as the speed of finger tapping for each hand for every subject. The group with left cerebral lesions tapped slower with the right than with the left hand by a mean of 9.00 taps. Conversely, the group with right cerebral lesions tapped slower with the left than the right hand by a mean of 9.52 taps. The difference between groups was statistically significant ($t = 6.57$; $p < .001$). A cut-off point that best differentiated the groups was determined for use in a subsequent cross-validation study.

A cross-validation study was performed in order to test the validity of a number of the principles relating to lateralization of brain dysfunction (11). A group of 17 patients with lesions of the left cerebral hemisphere and a group of 15 patients with lesions of the right cerebral hemisphere were used. Each of the criteria tested permitted binary classification of the patients in each group. The value used as a basis for determining the hand with the better performance on the Tactual Performance Test and the Finger Tapping Test were those obtained in the studies supporting Principles 15 and 16. The results of this cross-validation study are shown in the table on the next page.

Clearly the results shown in the table closely support those reported in various statements of principles above. The principles which reported excellent differentiation of patients according to lateralization of brain lesions also show excellent differentiation in the table. In addition, in instances in which a particular criterion yielded helpful results for patients with damage to one hemisphere but not for patients with damage of the other hemisphere (e.g., visual and auditory suppression in Principle 10),

CATEGORIZATION OF INDIVIDUAL PATIENTS ACCORDING TO CRITERIA RELATED TO
LATERALIZATION OF CEREBRAL LESIONS.

	<u>Left Cerebral Lesions; N= 17</u>	<u>Right Cerebral Lesions; N= 15</u>
<u>Wechsler-Bellevue</u>		
VWS > FWS	4	13
FWS > VWS	13	0
<u>Tactual Performance Test</u>		
Rt. Hand > Lt. Hand	1	15
Lt. Hand > Rt. Hand	16	0
<u>Finger Tapping Test</u>		
Rt. Hand > Lt. Hand	4	11
Lt. Hand > Rt. Hand	13	4
Dysphasia	12	1
Construction dyspraxia	0	10
Dystereognosis - right	6	0
Dystereognosis - left	1	8
Finger dysgnosia - right	7	1
Finger dysgnosia - left	0	8
Tactile suppression - right	5	0
Tactile suppression - left	1	8
Auditory suppression - right	2	0
Auditory suppression - left	1	6
Visual suppression - right	2	0
Visual suppression - left	1	11

> signifies "better than"

similar results were obtained in the cross-validation study. The incidence of findings relating to damage of the right or left cerebral hemisphere were determined for each of the 32 patients included in this study. The group with lesions of the left hemisphere had a mean of 4.47 positive signs for the left cerebral hemisphere and 0.76 positive signs for the right hemisphere. Comparison of these means indicated a highly significant difference ($t= 6.40$; $p < .001$). The 15 patients with lesions of the right cerebral hemisphere had a mean of 6.00 positive signs relating to dysfunction of the right hemisphere and a mean of 0.40 signs relating to dysfunction of the left hemisphere. This difference was also significant statistically ($t= 8.48$; $p < .001$). Every patient in the group with left cerebral lesions had an equal or greater number of positive signs for the left hemisphere than for the right hemisphere. Every patient in the group with right cerebral lesions had at least two more positive signs for involvement of the right hemisphere than for the left hemisphere. The difference in number of signs, therefore, would permit correct classification of each of the 32 subjects to his appropriate group, but obviously this procedure capitalizes on the chance characteristics of the two distributions.

References

1. Reitan, R. M.: An investigation of the validity of Halstead's measures of biological intelligence. *A.M.A. Arch. Neurol. Psychiat.*, 1955, 73:28-35.
2. _____.: The relation of the Trail Making Test to organic brain damage. *J. consult. Psychol.*, 1955, 19:393-394.
3. _____.: The validity of the Trail Making Test as an indicator of organic brain damage. *Percept. & Motor Skills*, 1958, 8:271-276.
4. _____.: The comparative effects of brain damage on the Halstead Impairment Index and the Wechsler-Bellevue Scale. *J. clin. Psychol.*, 1959, 15:281-285.

5. _____.: The predictive significance of dysphasia regarding the presence or absence of brain damage. (Not yet published).
6. _____.: The comparative frequency of dysphasia and related symptoms in patients with maximal damage in the left or right cerebral hemisphere. (Not yet published).
7. _____.: Certain differential effects of left and right cerebral lesions in human adults. *J. comp. physiol., Psychol.*, 1955, 48:474-477.
8. Kløve, H.: The relationship of differential electroencephalographic patterns to the distribution of Wechsler-Bellevue scores. *Neurology*, 1959, 9:871-876.
9. Kløve, H. and Reitan, R. M.: The effect of dysphasia and spatial distortion on Wechsler-Bellevue results. *A.M.A. Arch. Neurol. Psychiat.*, 1958, 80:708-713.
10. Reitan, R. M. and Tarshes, E. L.: Differential effects of lateralized brain lesions on the Trail Making Test. *J. nerv. ment. Dis.*, 1959, 129:257-262.
11. Reitan, R. M.: Some recent contributions of experimental psychology to psychopathology: Contributions from physiological psychology. (Symposium: *Midwestern Psychol.Assn.*, Detroit, 1958).

HYPOTHESES SUPPORTED BY CLINICAL EVIDENCE THAT ARE
UNDER CURRENT INVESTIGATION

Ralph M. Reitan, Professor of Psychology (Neurology) and
Hallgrim Kløve, Assistant Professor of Neurology

A number of hypotheses have been developed concerning patterns of psychological test results that seem to relate to both the locations and types of brain lesions. Some of these hypotheses have been born out by results on many individual patients and we feel quite confident that they will be supported by the results of controlled investigations. Other hypotheses have been included that have only recently been formulated. Our research has not yet progressed to the point of formal testing of these hypotheses under adequately controlled conditions.

1. Aphasic symptoms mainly receptive in nature, involving visual and auditory avenues, imply damage in the posterior temporal and adjacent cortical areas of the left hemisphere (visual form agnosia, visual letter agnosia, alexia, auditory verbal agnosia, auditory number agnosia, paraphasia).

2. Aphasic symptoms mainly expressive in nature imply damage in the posterior frontal and adjacent cortical areas of the left hemisphere (anomia, spelling apraxia, agraphia).

3. Little or no difference between Performance Weighted Score and Verbal Weighted Score on the Wechsler-Bellevue Scale detracts substantially from the likelihood of the presence of a rapidly growing, infiltrating lesion or destructive cerebrovascular accident in either hemisphere.

4. If the Picture Arrangement subtest on the Wechsler-Bellevue is

outstandingly low, a lesion in the anterior right temporal area is implied.

5. If the Block Design subtest on the Wechsler-Bellevue is outstandingly low, a lesion in the right parietal area is implied. *Mc Fic*

6. If the Similarities subtest on the Wechsler-Bellevue is outstandingly low, a lesion in the left temporal lobe may be present. However, a score on Similarities in line with the other verbal subtests does not necessarily imply a healthy left temporal lobe. *700*

7. An outstandingly low score on Picture Arrangement without much difference between Verbal and Performance Weighted Scores implies a relatively static lesion in the right anterior temporal lobe.

8. An outstandingly low score on Block Design without much difference between Verbal and Performance Weighted Scores implies a relatively static lesion in the right parietal lobe.

9. A lowered Performance Weighted Score is more commonly found with acute destructive lesions of the right hemisphere than is a lowered Verbal Weighted Score with the same type of lesions in the left hemisphere. Thus, our results suggest that the Performance Scale is more sensitive to lesions in the right hemisphere than the Verbal Scale is to lesions in the left hemisphere.

10. Suppression through tactual, auditory, and visual avenues implies maximal involvement in the area posterior to the Rolandic fissure.

11. Absence of any suppression argues against an acute, destructive lesion (glioma, cerebrovascular accident, etc.) in the posterior part of the hemispheres.

12. Auditory suppression implies maximal damage in the temporal lobe contralateral to the side on which suppression occurs.

13. There is a considerably greater likelihood of finding suppression with lesions in the right hemisphere than with lesions in the left hemisphere even in cases with malignant, rapidly developing infiltrating lesions.

14. Upper quadrant visual suppression implies maximal involvement in the corresponding temporal lobe.

15. Suppression with ipsilateral simultaneous stimulation or inconsistent suppression on both sides with bilateral simultaneous stimulation implies severe and diffuse damage to both hemispheres.

16. An outstandingly poor performance on the Halstead Speech Perception Test implies a lesion in the posterior part of the left temporal lobe.

17. Handedness rarely bears a relationship to the hemisphere subserving speech functions. (The left hemisphere customarily serves speech function even in left-handed persons).

18. If finger tapping appears to be more impaired than the performance with the same hand on the Tactual Performance Test, a location of the lesion in the anterior part of the hemisphere is suggested.

19. If the performance on the Tactual Performance Test appears to be more impaired than finger tapping with the same hand, a location of the lesion in the posterior part of the hemisphere some distance from the motor strip is suggested.

20. If both the Category Test and Part B of the Trail Making Test are poorly performed and other tests are on a near normal level, a focal and static lesion of one or both anterior frontal lobes is implied.

21. Impaired perception of finger-tip number writing implies maximal damage in the parietal area contralateral to the impaired hand.

22. Tests most sensitive to any organic impairment of brain functions are ones requiring alertness, concentrated and sustained attention to the task and, probably most important, sufficient complexity so that adequate performance may be limited even in patients in whom only rather specific abilities are impaired. (This hypothesis argues against procedures using two relatively "pure" measurements in the form of a ratio as an indicator of brain function).

ADDITIONAL RESEARCH CONCERNED WITH THE PSYCHOLOGICAL
EFFECTS OF BRAIN DAMAGE

A number of additional studies from the Neuropsychology Laboratory of the Indiana University Medical Center have been concerned with a variety of questions regarding the psychological effects of brain damage, even though they have not contributed specifically to the principles used for interpretation of the test results. These studies may be grouped under the following categories: (a) the methodology and approach to be used in measuring the psychological concomitants of brain dysfunction, (b) the nature of psychological impairment associated with brain damage, (c) psychological effects of specific diseases or conditions with neurological sequelae, and (d) illustration of the types of loss in abilities as a result of lesions in various areas of the brain.

Methodology and Approach in Neuropsychology:

12. Reitan, R. M.: Investigation of relationships between "psychometric" and "biological" intelligence. *J. nerv. ment. Dis.*, 1956, 123:536-541.
13. _____.: Qualitative versus quantitative mental changes following brain damage. *J. Psychol.*, 1958, 46:339-346.
14. _____.: Impairment of abstraction ability in brain damage: Quantitative versus qualitative changes. *J. Psychol.*, 1959, 48:97-102.
15. _____.: The comparative behavioral effects of phenaglycodol, meprobamate, and placebo. (In *Drugs and Behavior*, James G. Miller and Leonard Uhr, eds.). John Wiley & Sons, 1960.
16. Kløve, H.: Hypotheses and methods relative to lateralization and localization of cerebral lesions. *Proc. XVth Intntl. Congr. Psychol.*, Brussels, Belgium, 1957.
17. Reitan, R. M.: Neural mechanisms and "thinking." *Amer. Acad. Neurol. Research Symposium*, Philadelphia, 1958.

18. Reitan, R. M.: Effects of brain damage on a psychomotor problem solving task. *Percept. Motor Skills*, 1959, 9:211-215.
19. Kløve, H., and Grosz, H.: The effects of hypnotically induced anxiety or depression on psychological measures sensitive to organic brain damage. (Not yet published).

Nature of Psychological Impairment Associated with Brain Damage:

20. Reitan, R. M.: Intellectual functions in aphasic and non-aphasic brain-injured subjects. *Neurology*, 1953, 3:202-212.
21. _____.: Intelligence and language functions in dysphasic patients. *Dis. Nerv. System*, 1954, 15:2-8.
22. _____.: The performance of aphasic, non-aphasic, and control subjects on the Rorschach Test. *J. gen. Psychol.*, 1954, 51:199-212.
23. Heimburger, R. F., and Reitan, R. M.: Testing for Aphasia and Related Disorders. (Mimeographed manuscript, Pp. 1-67).
24. Reitan, R. M.: The psychological significance of dysphasia as a specific symptom of brain damage. (Not yet published).
25. Reitan, R. M., and Kløve, H.: The frequency of occurrence of various dysphasic symptoms. (Not yet published).
26. Reitan, R. M.: Validity of Rorschach Test as a measure of the psychological effects of brain damage. *A.M.A. Arch. Neurol. Psychiat.*, 1955, 73:445-451.
27. _____.: Affective disturbances in brain-damaged patients: Measurements with the Minnesota Multiphasic Personality Inventory. *A.M.A. Arch. Neurol. Psychiat.*, 1955, 73:530-532.
28. _____.: Relation of Rorschach Test ratios to brain injury. *J. gen. Psychol.*, 1955, 53:97-107.
29. _____.: Impairment of abstraction ability in patients with lesions of the left or right cerebral hemisphere. (Not yet published).
30. Reitan, R. M., and Kløve, H.: Identifying the brain-injured child. In Clinical Studies III, The Univ. of Chicago Press. (In Press).
31. Kløve, H.: The relationship of sensory suppression to distribution of Wechsler-Bellevue scores. *Midwest. Psych. Assn.*, Chicago, 1959.
32. _____.: Den diffensielle effekt av lesjoner i høyre og venstre hemisfære. (The differential effect of lesions in the right and left hemispheres.) *Nordisk Psykologi (Nordic Psychology)*, 1960, 12:138-140.

33. Kløve, H., White, P. T., and Taylor, R.: Correlation of EEG and Neuropsychological studies in organic brain disease. *Electroenceph. Clin. Neurophysiol.*, 1959, 11:844.
34. _____: The relationship of degree of electroencephalographic abnormality to the distribution of Wechsler-Bellevue scores. *Midwest. Psychol. Assn., St. Louis*, 1960.
35. Kløve, H., and White, P. T.: The effects of epileptic seizures on intellectual functioning. (To be published).
36. Doehring, D. G., and Reitan, R. M.: MMPI performance of aphasic and nonaphasic brain-damaged patients. *J. clin. Psychol.*, 1960, 16:307-309.
37. Fitzhugh, K. B., Fitzhugh, L. C., and Reitan, R. M.: Psychological deficits in relation to acuteness of brain dysfunction. (In Press, *J. consult. Psychol.*)
38. Reitan, R. M.: The significance of dysphasia for intelligence and adaptive abilities. *J. Psychol.*, 1960, 50:355-376.
39. Reitan, R. M.: Correlations between the Trail Making Test and the Wechsler-Bellevue Scale. *Percept. Motor Skills*, 1959, 9:127-130.
40. Heimburger, R. F., and Reitan, R. M.: Easily administered written tests for lateralizing brain lesions. (Submitted for publication).

Psychological Effects of Specific Diseases or Conditions with Neurological

Sequelae:

41. Reitan, R. M.: Intellectual functions in myxedema. *Arch. Neurol. Psychiat.*, 1953, 69:436-449.
42. _____: Intellectual and affective functions in chronic brucellosis. *Amer. J. Psychiat.*, 1953, 110:19-28.
43. _____: Intellectual and affective changes in essential hypertension. *Amer. J. Psychiat.*, 1954, 110:817-824.
44. _____: Evaluation of the postconcussion syndrome with the Rorschach Test. *J. nerv. ment. Dis.*, 1955, 121:463-467.
45. Russell, J. R., and Reitan, R. M.: Psychological abnormalities in agenesis of the corpus callosum. *J. nerv. ment. Dis.*, 1955, 121:205-214.
46. Ross, A. T., and Reitan, R. M.: Intellectual and affective functions in multiple sclerosis: A quantitative study. *A.M.A. Arch. Neurol. Psychiat.*, 1955, 73:663-677.
47. Reitan, R. M.: The comparative effects of placebo, Ultram, and meprobamate on psychologic test performances. *Antibiotic Med. & Clin. Therapy*, 1957, 4:158-165.

48. Reitan, R. M.: The distribution according to age of a psychologic measure dependent upon organic brain functions. *J. Gerontol.*, 1955, 10:338-340.
49. _____.: The relationship of the Halstead Impairment Index and the Wechsler-Bellevue total weighted score to chronological age. *J. Gerontol.*, 1956, 11:447.
50. _____.: Differential reactions of various psychological tests to age. *Proc. Fourth Intl. Gerontol. Congress, Merano and Venice, Italy, 1957.*
51. _____.: The comparative psychological significance of aging in groups with and without organic brain damage. *Proc. Fifth Intl. Gerontol. Congress, San Francisco, U.S.A., 1960.*
52. Kløve, H.: The differential relationships of psychological test results to electroencephalographic criteria in older and younger age groups. *Proc. Fifth Intl. Gerontol. Congress, San Francisco, U.S.A., 1960.* (In press).
53. Heimbürger, R. F., DeMyer, W., and Reitan, R. M.: The neurological significance of Gerstmann's syndrome. *Amer. Acad. Neurol.*, Boston, 1957.
54. Reitan, R. M., DeMyer, W., and Heimbürger, R. F.: The psychological significance of Gerstmann's syndrome. *Amer. Acad. Neurol.*, Boston, 1957.
55. Doehring, D. G., and Reitan, R. M.: Behavioral consequences of homonymous visual field defects in brain injured adults. (Submitted for publication).
56. Doehring, D. G., Reitan, R. M., and Kløve, H.: Changes in patterns of intelligence test performance associated with homonymous visual field defects. (Submitted for publication).
57. Doehring, D. G., and Reitan, R. M.: Certain language and nonlanguage disorders in brain-damaged patients with homonymous visual field defects. (Submitted for publication).
58. Fitzhugh, L. C., Fitzhugh, K. B., and Reitan, R. M.: Adaptive abilities and intellectual functioning in hospitalized alcoholic subjects. *Quart. J. Stud. Alcohol.*, 1960, 21:414-423.

Illustrations of Types of Psychological Losses with Brain Damage:

59. Reitan, R. M.: Differential patterns of psychological test results in lateralized and localized cerebral lesions. *Proc. XVth Intl. Congr. Psychol.*, Brussels, Belgium, 1957.
60. _____.: Behavioral disabilities associated with brain damage. *Education* (In press).

DESCRIPTION OF BATTERY OF PSYCHOLOGICAL TESTS

Halstead's Neuropsychological Test Battery¹Impairment Index:

The Impairment Index is a composite score based upon the 10 "discriminating" tests in the Halstead battery and is determined for an individual subject merely by counting the number of tests which fall above the criterion level.

Category Test:

The Category Test utilizes a projection apparatus for presentation of stimulus material. The subject is required to "abstract" principles based upon variables such as size, shape, number, position, brightness, and color around which to organize his responses.

Critical Flicker Frequency and Critical Flicker Frequency Deviation:

In the Flicker Fusion Test an electronic instrument (Strobotac) with a short flash duration, housed in a specially constructed, soundproof apparatus, is used. This test involves the measurement of the point at which a variably intermittent light fuses into the appearance of a steady light. The subject is required to adjust a control knob until the flashing rate of the light is increased to the point where fusion is reached and the light appears steady to him.

Tactual Performance Test: Time, Memory and Localization:

The Tactual Performance Test utilizes a modification of the Seguin-Goddard form board. The subject is blindfolded and is not permitted to see the form board or blocks at any time. He first fits the blocks into their

¹Halstead, W. C.: Brain and Intelligence: A Quantitative Study of the Frontal Lobes, Chicago, University of Chicago Press, 1947.

proper spaces with his preferred hand, then repeats the procedure with his other hand, and finally performs the task a third time using both hands. After the board and blocks have been put out of sight, the blindfold is removed and the subject is required to draw a diagram of the board representing the blocks in their proper spaces. The subject is scored for the total time needed to place the blocks on the board. The Memory Component of this test is based upon the number of blocks correctly reproduced in the drawing of the board, and the Localization Component is based on the number of blocks correctly localized.

Rhythm Test:

The Rhythm Test is a subtest of the Seashore Test of Musical Talent. The subject is required to differentiate between pairs of rhythmic beats which are sometimes the same and sometimes different.

Speech-sounds Perception Test:

The Speech-sounds Perception Test consists of 60 spoken nonsense words which are variants of the "ee" sound presented in multiple choice form. The test is played from a tape recorder with the intensity of sound adjusted to the subject's preference. The subject's task is to select the spoken syllable from the alternatives printed on the test form.

Finger Oscillation Test:

The Finger Oscillation Test is a measure of tapping speed, the subject using the index finger, first of the preferred hand and then the other hand. The subject is allowed five consecutive trials of 10 seconds each for both hands.

Time Sense Test: Visual and Memory:

The Time Sense Test requires the subject to depress a key which

permits a sweep-hand to rotate on the face of a clock. The subject's task is to allow the hand to rotate 10 times and then to stop it as close to the starting position as possible. The Visual Component of this test is scored as the amount of error in 40 trials. Then the face of the clock is turned away and the subject is asked to duplicate the visually controlled performance as closely as possible. Thus the Memory Component is the error on 20 trials interspersed among the visual trials in a series of 10.

Trail Making Test:

The Trail Making Test consists of two parts, A and B. Part A consists of 25 circles distributed over a white sheet of paper and numbered from 1 to 25. The subject is required to connect the circles with a pencil line as quickly as possible, beginning with the number 1 and proceeding in numerical sequence. Part B consists of 25 circles numbered 1 to 13 and lettered from A to L. The subject is required to connect the circles, alternating between numbers and letters as he proceeds in ascending sequence. The score is obtained as the number of seconds needed to finish each part.

Aphasia Examination:

The aphasia examination that we use is a modification of the Halstead-Wepman aphasia screening test. The Halstead-Wepman test was modified by omitting a number of items for which we rarely found positive results, and have added several additional procedures that often turn out to be very helpful. Some of the additional procedures test for symptoms related to aphasia, such as finger agnosia, finger-tip number writing recognition, and

tactile, auditory, and visual suppression phenomena.

Wechsler-Bellevue: (Form I)

This test is well known and is used in the standard way.

Minnesota Multiphasic Personality Inventory:

The individual form of this test is used.

Tests still in an examination phase include the Word Finding Test, Spokes Test, and Miles' ABC Test of ocular dominance.

OPERATING PROCEDURES OF THE NEUROPSYCHOLOGY LABORATORY

The neurosurgeons and neurologists at the Indiana University Medical Center have become familiar with the types of patients necessary for investigation in the research currently underway at the Neuropsychology Laboratory. Patients are referred to the laboratory by these physicians. The criterion they apply with respect to referrals is whether or not the individual patient may be appropriate for the research. In other words, the basic question concerns whether or not we may be able to learn something from testing the patient.

Technicians in the laboratory take the referrals and perform the testing. Customarily the psychologists who write interpretations of the test results have never seen the patient. The interpretations are written from the test results alone except for brief descriptions about the patient including age, education, handedness, sex, and sometimes occupation.

Interpretation of the test results is a complex procedure that cannot be described briefly. Study of the results on individual patients, the report written on the basis of the test results, and the retrospective comment on the interpretation of the results should be helpful in communicating and understanding of how the interpretation for individual patients proceeds.

Reitan, R. M.: Investigation of the validity of Halstead's measures of biological intelligence. A.M.A. Archives of Neurology and Psychiatry, January 1955, Vol. 73, pp. 28-35.

Subjects matched in pairs for color, sex, age, and education. Control mean age and education; 32.36 years and 11.58 years. Brain damage mean age and education; 32.42 years and 11.56 years.

<u>Category Test</u>	<u>N=50 Controls</u>	<u>N=50 Brain-Damage</u>	<u>Halstead's Cut-off point</u>	
			<u>Controls</u>	<u>Brain-Damage</u>
Mean	32.38	61.98	0 - 50 errors	51 or more errors
S.D.	12.62	21.82		
<u>CFF - Cps.</u>				
Mean	22.71	22.11	21.0 and above	20.9 and below
S.D.	3.95	3.92		
<u>CFF - Dev.</u>				
Mean	.7360	.6960	.7 and above	15.7 and above
S.D.	.36	.42		
<u>TPT - Time</u>				
Mean	12.59	25.19	15.6 and below	15.7 and above
S.D.	5.20	12.67		
<u>TPT - Memory</u>				
Mean	7.65	5.92	6 and above	5 and below
S.D.	1.41	1.75		
<u>TPT - Localization</u>				
Mean	5.29	1.88	5 and above	4 and below
S.D.	2.12	1.74		
<u>Seashore Rhythm</u>				
Mean	5.20	8.46	5 and below	6 and above
S.D.	3.45	2.62		
<u>Speech Perception</u>				
Mean	7.08	14.06	7 and below	8 and above
S.D.	5.31	8.48		
<u>Tapping Test</u>				
Mean	50.74	45.58	51 and above	50 and below
S.D.	7.29	7.32		

<u>Time Sense-Memory</u>	N=50 <u>Controls</u>	N=50 <u>Brain-Damage</u>	Halstead's Cut-off point	
			<u>Controls</u>	<u>Brain-Damage</u>
Mean	293.44	523.54	260 and below	261 and above
S.D.	217.59	587.16		
<u>Impairment Index</u>				
Mean	.3240	.6920	.4 and below	.5 and above
S.D.	.14	.16		

Reitan, R. M.: Validity of the Trail Making Test as an indicator of organic brain damage. *Perceptual and Motor Skills*, 1958, 8, 271-276.

Means of control group for age and education; 33.45 years and 11.19 years. Means of brain-damaged group for age and education; 34.88 years and 10.56 years.

<u>Part A</u> <u>Trail Making Test</u>	N=84 <u>Controls</u>	N=200 <u>Brain-Damage</u>	Cut-off point	
			<u>Controls</u>	<u>Brain-Damage</u>
Mean	9.46	6.24	Not used for this part.	
S.D.	1.13	3.11		
<u>Part B</u> <u>Trail Making Test</u>				
Mean	5.73	1.84	4 and above	3 and below
S.D.	2.40	1.30		

Name E. E. Date Tested 10-28-54
 Hospital Carter & Long Ward _____ Hospital No. _____
 Birthdate 12-1-11 Age 42 Education 7 Handedness Right
 Sex Male Occupation Carpenter

Word Finding		W-B (Form I):	Category I II:	
Hemmon-Nelson		VIQ	1 0 2 0 3 9	<u>414</u>
Spokes A		PIQ	534 633 7 8	<u>98</u>
Spokes B		F-S IQ	Flicker - Cps	
Trails A I II	<u>105"-2</u>	VWS	Dev	
Trails B I II	<u>379"-1</u>	PWS	TPT I II III:	
Trails Total	<u>484"-3</u>	Tot WS	RH <u>14.9</u>	Time <u>33.3</u>
		Inf	LH <u>13.7</u>	Mem <u>1</u>
MMPI:		Comp	BH <u>4.6</u>	Loc <u>1</u>
? _____ Pd _____		Digit Sp	Seashore Rhythm	<u>10</u>
L _____ Mf _____		Arith	Raw Score <u>13</u>	
F _____ Pa _____		Simil	Speech Percept I II	<u>33</u>
K _____ Pt _____		Vocab	Tapping: RH <u>36</u>	<u>36</u>
Hs _____ Sc _____		P Arr	LH <u>31</u>	
D _____ Ma _____		P Comp	Time Sense - Memory	<u>1509.6</u>
Hy _____		Bl Des	Visual <u>67.4</u>	
		Obj Assem		
7) ABC: R <u>1</u> L <u>9</u>		Digit Sym	Impairment Index	<u>1.0*</u>

Aphasic Symptoms: Dysnomia, dyslexia, dyscalculia, dysgraphia, dysarthria, spelling dyspraxia, visual letter dysgnosia.

Report of Neuropsychological Examination

This 42-year-old man obtained a Full-Scale Wechsler-Bellevue (Form I) IQ of 75 (Verbal IQ, 73; Performance IQ, 82). The pattern of these results suggests the premorbid level was in the low-average range. The measures of biological intelligence yielded an Impairment Index of 1.0, indicating severe impairment of adaptive abilities dependent upon organic brain functions. The test results indicate impairment of function in the left as compared with the right hemisphere, but impaired function occurs throughout the cerebral cortex. The results are compatible with a fairly large intrinsic tumor of the left hemisphere, exerting widespread effects, but located structurally primarily in the left temporal lobe extending anteriorly to involve the posterior frontal lobe and possibly including the inferior parietal area as well. Dysphasic symptoms included dysnomia, dyslexia, dyscalculia, dysgraphia, dysarthria, spelling dyspraxia, and visual letter dysgnosia.

RMR

Comment

The general level of performance on the tests was quite poor and in the range characteristic of acutely destructive brain lesions. The location of the lesion was based principally upon the dysphasic symptoms. Although the Tactual Performance Test and Tapping Test did not help in lateralization, the dysphasia could not be discounted. (As a general rule, the occurrence of definite dysphasia seems to take precedence over any other indicators for a positive

NB

E. E. (Continued)

conclusion of damage in the left cerebral hemisphere. The dysphasic symptoms were both expressive and receptive. Some posterior frontal involvement was implied by the expressive difficulties of dysnomia and dysgraphia. The receptive dysphasia (visual letter dysgnosia and dyslexia) are rarely seen without some posterior left temporal involvement. The level of impairment was consistent with an intrinsic tumor or a destructive cerebral vascular accident within an anatomical area indicated above. A cerebral vascular accident in this area would almost certainly have caused some motor impairment in the right as compared with the left upper extremity. Thus, an intrinsic tumor seemed to be the most likely possibility in terms of the type of lesion. While the posterior frontal-temporal area was identified as dysfunctional by the dysphasic symptoms, the absence of finger dysgnosia and dystereognosis of the right hand argued that the lesion did not involve the left parietal area to any major extent.

Neurological and Neurosurgical Summary

Symptoms: Numbness, right leg, 4 months.
Numbness, right arm, 3 months.
Convulsions, head and eyes turned to the right, 1 month.
Frontal headaches, 1 month.
Nausea and vomiting, 1 week.

Signs: Confused, lethargic.
Neurological examination normal, no papilledema.

Handedness: Right.

Diagnostic Tests: 10-28-54: Carotid angiography.
10-29-54: Tested for aphasia.

Treatment: 11-1-54: Fronto-temporal craniotomy, left.
Partial removal of glioma.
Amputation left frontal lobe of brain.

Postoperative Course: Able to talk one week postoperative.
Right hemiparesis, able to use arm and hand for gross movements.
Able to walk with help.
Died at home 1½ months postoperative.
No autopsy allowed.

Diagnosis: Glioblastoma multiforme (astrocytoma grade III), fronto-temporal, left.

RFH

PSYCHOLOGICAL TESTS ADMINISTERED BEFORE SURGERY



clock


Square

cross

seven



$$\begin{array}{r}
 85 \\
 24 \\
 \hline
 61
 \end{array}$$



He should be warrened

Name F. C. Date Tested 3-28-56
 Hospital Long Ward C Hospital No. _____
 Birthdate 1-21-94 Age 62 Education 10 Handedness Right
 Sex Male Occupation Ground man on line crew

Word Finding		W-B (Form I):	Category I II:	
Hemmon-Nelson	<u>55</u>	VIQ	<u>94</u>	1 0 2 1 3 25 4 20
Spokes A		PIQ	<u>98</u>	
Spokes B		F-S IQ	<u>92</u>	
Trails A I II	<u>61"-6</u>	VWS	<u>33</u>	Flicker - Cps
Trails B I II	<u>191"-1</u>	PWS	<u>23</u>	Dev
Trails Total	<u>252"-7</u>	Tot WS	<u>56</u>	TPT I II III:
		Inf	<u>8</u>	RH <u>13.5</u>
MMPI:		Comp	<u>9</u>	LH <u>12.8</u>
? <u>50</u>	Pd <u>55</u>	Digit Sp	<u>4</u>	BH <u>8.4</u>
L <u>66</u>	Mf <u>59</u>	Arith	<u>7</u>	Seashore Rhythm
F <u>50</u>	Pa <u>62</u>	Simil	<u>5</u>	Raw Score <u>24</u>
K <u>55</u>	Pt <u>50</u>	Vocab	<u>4</u>	Speech Percept I II
Hs <u>47</u>	Sc <u>53</u>	P Arr	<u>3</u>	Tapping: RH <u>33</u>
D <u>72</u>	Ma <u>50</u>	P Comp	<u>4</u>	LH <u>38</u>
Hy <u>64</u>		Bl Des	<u>5</u>	Time Sense - Memory
		Obj Assem	<u>7</u>	Visual <u>65.0</u>
ABC: R <u>10</u>	L <u>0</u>	Digit Sym	<u>4</u>	Impairment Index
				<u>0.9</u>

Aphasic Symptoms: None.

Report of Neuropsychological Examination

This 62-year-old right-handed man obtained a Full-Scale Wechsler-Bellevue (Form I) IQ of 92 (Verbal IQ, 94; Performance IQ, 98). The tests of biological intelligence yielded an Impairment Index of 0.9, which is consistent with moderately severe impairment of adaptive abilities dependent upon organic brain functions. In a person of this age an Impairment Index of this magnitude is not specifically indicative of an acute organic brain change or a statistically deviant result since many persons in this age range without neurological complaints or findings show elevated Impairment Indexes. More specifically, however, this patient performed sufficiently poorly on certain tests to indicate the presence of brain damage. He gave evidence of a definite dysgnosia of fingers 2, 3, and 4 of the right hand and also was able to tap (in 10 seconds) at a rate of 33 times with his right hand as compared with 38 times with his left hand. These findings suggest a lesion in the left hemisphere. However, there was no evidence of organic language loss in the aphasia examination and, in fact, on more complex language tests the patient performed actually somewhat better than his level of performance on motor tests. These results indicating sparing of language function, finger dysgnosia in the right hand, and a distinct loss of tapping speed in the right hand all suggest that the lesion is located in the region of the Rolandic fissure of the left hemisphere. Our estimate would be that it is primarily in the left parietal area although the adjacent frontal tissue may also be somewhat involved. Sparing of language functions and the finger dysgnosia suggest that the lesion is fairly high on the convex surface of the hemisphere.

The level and pattern of results are not what we usually obtain with intrinsic tumors. This patient's abilities should have been more generally suppressed by a glioma and some dysphasia would likely have been present.

F. C. (Continued)

It would seem more likely that the lesion is more of an irritative type, possibly a residual development of head trauma. An additional finding supporting this belief is that of a fairly specific dysfunction in the right temporal area, a type of finding often encountered in cases of fairly severe closed head injury.

RMR

Comment

The findings relating to dysfunction in the left cerebral hemisphere are noted fairly explicitly above, but we should also note that the patient was unable to recognize numbers written on his right thigh in most instances but had no difficulty in recognizing numbers written on his left thigh. The findings suggesting dysfunction in the right hemisphere were not nearly as pronounced as those suggesting left hemisphere dysfunction. The results on Picture Arrangement and Block Design seemed a little low, the patient did not copy a cross quite as well as we would customarily expect, and he reversed the direction of the stimulus figure in copying a key. Retrospectively, we would not imply an area of involvement as focal as the right temporal lobe to account for these findings. They appear to be more compatible with mild dysfunction of the right temporo-parietal area.

Neurological and Neurosurgical Summary

Symptoms: Right hemiparesis, starting suddenly at night February, 1952. Patient cried out and was found on floor unconscious. Hemiparesis lasted 8-12 hours, and was amnesic during that time. "Black out" in June, 1952 accompanied by drawing of feet and toes followed by weakness of right arm. Scattered seizures after that. Struck head during attack in August 1955 and received bruise, 1-5 attacks per day since, not severe.

Signs: Neurological examination normal.

Handedness: Right .

Diagnostic CSF, OP 180 mm Protein 85 mgm%.

Tests: Normal skull films.
Normal carotid angiograms bilaterally.
Normal encephalogram.
EEG Grade I dysrhythmia left Sylvian.
Diffuse cerebral atrophy.

Course: Phenobarb. 100 mgm tid controlled convulsions while he was in hospital.
Discharged, 4-3-56. Failed to return to clinics.

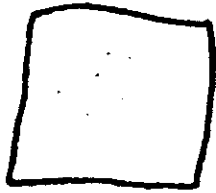
Diagnosis: Cortical atrophy, with convulsions due to irritation of left motor area of brain.

Addenda: Head injury at age 19 years, unconscious 6 hours, headache 3 days.

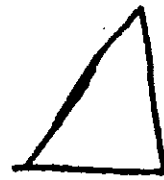
RFH




1.



2.




F. C.



Clock.
Square
square

He shouted the warning

$$\begin{array}{r} 85 \\ 27 \\ \hline 58 \end{array}$$



Name V. G. Date Tested 2-18-57
 Hospital Long Ward D
 Birthdate 9-13-09 Age 47 Education 8 Hospital No. Right
 Sex Male Occupation Pool Grinder Handedness Right

Word Finding		W-B (Form I)	Category I	II	III	
Hemmon-Nelson	57	VIQ	1	2	3	81
Spokes A	44	PIQ	5	6	7	96
Spokes B	219	F-S IQ				88
Trails A I II	59=6	VWS				29
Trails B I II	289=1	PWS				33
Trails Total	348=7	Tot WS				62
		Inf				10
MMPI:		Comp				7
? 50	Pd 81	Digit Sp				4
L 80	Mf 57	Arith				6
F 64	Pa 59	Simil				2
K 46	Pt 66	Vocab				6
Hs 70	Sc 65	P Arr				6
D 77	Ma 65	P Comp				6
Hy 73		Bl Des				7
		Obj Assem				10
ABC: R 10	L 0	Digit Sym				4
			Seashore Rhythm			19
			Raw Score			15
			Speech Percept I II			48
			Tapping: RH			19
			LH			19
			Time Sense	Memory		88.7
			Visual	100.5		
			Impairment Index			0.7

Aphasic Symptoms: Spelling dyspraxia, mild dysgraphia, mild dyscalculia, finger dysgnosia and impaired finger-tip number writing perception on left hand.

Report of Neuropsychological Examination

This 47-year-old man obtained a Full-Scale Wechsler-Bellevue (Form I) IQ of 88 (Verbal IQ, 84; Performance IQ, 96). The tests of biological intelligence yielded an Impairment Index of 0.7 indicating moderate impairment of abilities dependent upon organic brain function. Analysis of the pattern of test results is indicative of generalized damage to both cerebral hemispheres, probably maximized in the anterior parts of the brain. It seems as if the part maximally involved in the right hemisphere is the fronto-parietal area including the motor strip, while maximum involvement in the left hemisphere appears to be in the inferior parietal and temporal areas, conceivably with some impairment of the posterior frontal area. An aphasia examination revealed the following symptoms: spelling dyspraxia, mild dysgraphia, and possible dyscalculia. Examination for tactile, auditory, and visual suppression gave negative results. Examination for dystereognosis revealed mild impairment in both hands without any appreciable difference. Finger agnosia was demonstrated for the 3rd and 4th fingers of the left hand and impaired perception of finger-tip number writing was also demonstrated on the left hand probably most pronounced for the 2nd, 3rd, and 4th fingers. These test results are not typical of a neoplastic lesion, but would be more compatible with either a lesion of long-standing or an extremely slow developing vascular abnormality affecting both hemispheres. Our best inference would be a fairly static lesion affecting both hemispheres but maximized in the right fronto-parietal area.

HK

V. G. (Continued)

Comment

This patient presented in his test results a picture of moderately severe generalized impairment of functions in both cerebral hemispheres. Presence of brain damage was evident from the Category Test score, the Localization component of the Tactual Performance Test, Trails B, and the Impairment Index. Disturbance of left hemisphere function was suggested by the dysphasic symptoms. Evidence of a lesion in the right hemisphere came from the slow performance with the left hand on the Tactual Performance Test, the low tapping speed of the left hand as compared with the right hand, a tendency toward mild tactile suppression of the left hand, mild finger dysgnosia of the left hand, and impaired perception of finger-tip number writing on the left hand. It appears that the difference between the two hands on the Finger Tapping Test was more marked than the reversal on the Tactual Performance Test. This observation combined with only mild signs of suppression and absence of definite construction dyspraxia would tend to place the area of maximal involvement close to the motor strip, but still posterior to the central sulcus because of the mild but definite parietal signs. Reasons for stating that these symptoms were not likely related to a neoplastic lesion were mainly on grounds of negative inferences. There was no substantial difference between the verbal and performance weighted scores on the W-B Scale, no predominant construction dyspraxia and only very mild suppression.

If the signs of bilateral involvement were to be accounted for in terms of a tumor or metastatic lesion, the general level of test results certainly would have been considerably poorer. Under these circumstances the underlying lesion almost had to be relatively static. A set of test results like these giving a picture of diffuseness, but with an area of definite focal involvement seems to be rather typical of vascular malformations.

Neurological and Neurosurgical Summary

Symptoms: In 1951, 6 years prior to admission, patient began having left-sided seizures involving the arm and leg without loss of consciousness. These episodes increased in frequency to the point that he has been unable to work during the past year. Seizures were not controlled by anticonvulsants. Stated to have weakness right arm and leg since birth.

Signs: Physical examination: Normal.
Neurological examination: Minimal left hemiparesis.

Handedness: Right.

Diagnostic CBC: Urine, normal.

Tests: CSF: Protein 21.

Serology, negative.

EEG: Dysrhythmia Grade II, right fronto-parietal area.

Angiogram: Bilateral carotids showed only enlarged ventricles.

Pneumoencephalogram: Absence of septum pellucidum. Ventricles enlarged, right more than left. Small herniation of right lateral ventricle in posterior frontal area seen on lateral view.

V. G. (Continued)

Treatment: 3-8-57: A right frontal-parietal craniotomy was done. A large abnormal vein was found in the area of the Rolandic fissure and crossing the Sylvian fissure. A large arachnoid cyst was found in the Sylvian area. The vein was removed and the cyst unroofed.

Postoperative The second day postoperatively he developed increasing lethargy.
Course: The wound was reopened and an extra dural hematoma removed. Following this he improved. Right carotid angiogram was repeated and no evidence of malformation was seen.


Diagnosis: Convulsive episodes, secondary to ? arteriovenous malformation, right Rolandic fissure.

JK


PSYCHOLOGICAL TESTS ADMINISTERED BEFORE SURGERY




1.



2.



Rock




Square

85-
27
68



1.



2.

*He short
He showed the waving*

Name C. B. Date Tested 7-9-56
 Hospital Long Ward G Hospital No. _____
 Birthdate 12-23-10 Age 45 Education 12 Handedness Right
 Sex Female Occupation Housewife

Word Finding	W-B (Form I):	Category I II:	
Hemmon-Nelson	VIQ	1 2 3 4	
Spokes A	PIQ	5 6 7	
Spokes B	F-S IQ	Flicker - Cps	
Trails A I II	VWS	Dev	
Trails B I II	PWS	TPT I II III:	
Trails Total	Tot WS	RH	Time
	Inf	LH	Mem
MMPI:	Comp	BH	Loc
? Pd	Digit Sp	Seashore Rhythm	
L Mf	Arith	Raw Score	
F Pa	Simil	Speech Percept I II	
K Pt	Vocab	Tapping: RH	
Hs Sc	P Arr	LH	
D Ma	P Comp	Time Sense - Memory	
Hy	Bl Des	Visual	
	Obj Assem		
ABC: R L	Digit Sym	Impairment Index	

Aphasic Symptoms: No organic language deficits. Construction dyspraxia, tendency to ignore the left side of stimulus configurations, occasional suppression on the left of bilateral simultaneous visual stimulation.

Report of Aphasia Examination

An aphasia examination was administered to this 45-year-old woman on July 9, 1956. Although no indications of organic language dysfunction were found, the patient gave defective performances in several respects. Her copying of a cross, while not grossly defective, was clearly distorted on two separate attempts. She also failed to achieve a proper spatial closure in attempting to copy a triangle. Nevertheless, she had no difficulty in writing either to dictation or in copying. In attempting to read, the patient would read only the last one or two words on the right side of each line, failing to respond to the words further to the left on each line. The patient showed no suppression phenomena through tactile or auditory avenues. On testing suppression of bilateral simultaneous visual stimulation, the procedure was complicated by what appeared to be a lower left quadrantic homonymous field defect. Nevertheless, when the stimulus was given in an area of the visual field to which the patient was able to respond, she occasionally suppressed the stimulus in her left field. There was no apparent astereognosis or finger dysgnosia.

These findings strongly suggest damage in the right hemisphere and suggest the possibility of neoplastic disease. Our best estimate of the location of the lesion from the symptoms is that it would involve the right temporo-frontal area.

RMR

C. B. (Continued)

Comment

Several of the findings in this patient are consistent with a severely destructive type of brain lesion. The tendency to ignore the symbolic significance of the left side of stimulus configurations occurs nearly exclusively in patients having progressive or destructive types of brain lesions (intrinsic brain tumors and cerebral vascular accidents). The differentiation of the specific condition was quite clear in this patient because a vascular lesion in the area of the motor strip would have been almost certain to give rise to sensory or motor impairment of the left upper extremity. The findings were consistent in indicating damage of the right cerebral hemisphere. No positive symptomatology was found to implicate the left cerebral hemisphere. The results required an anterior placement of the lesion in spite of the apparent lack of motor impairment of the left arm and hand because the patient had no finger dysgnosia nor dystereognosis of the left hand. A neoplastic lesion behind the Rolandic fissure would almost certainly have given rise to at least mild impairment of these types regardless of its area of maximal involvement. The only reason for extending the lesion structurally behind a frontal location was the left homonymous quadrantanopsia.

Neurological and Neurosurgical Summary

Symptoms: Headaches and lethargy.

Two years prior to admission patient had a generalized seizure. Six weeks prior to admission she developed severe headaches and blurring of vision. Memory had been impaired for an indefinite period. For two weeks prior to admission she had become progressively more lethargic and confused.

Signs: Lethargic, memory poor, confused and disoriented.

Disk margins blurred, left lower quadrant field defect, suppression on left, left Hoffman and left Babinski.

Handedness: Right.

Diagnostic Tests: EEG: Delta Grade II, maximal right Sylvian.

X-rays: Skull films negative. Chest films negative.

Ventriculogram: Large tumor in right frontal-parietal area with displacement of ventricular system to left and depression of frontal horn.


Treatment: 7-15-56: Craniotomy, right frontal. Large oligodendroglioma found. Frontal lobectomy done.

Postoperative Course: Expired second postoperative day.

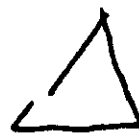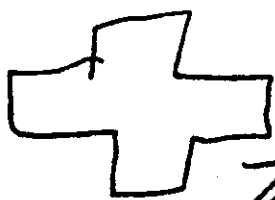
Diagnosis: Oligodendroglioma, right frontal lobe.

JK

PSYCHOLOGICAL TESTS ADMINISTERED BEFORE SURGERY



(1st attempt)



triangle

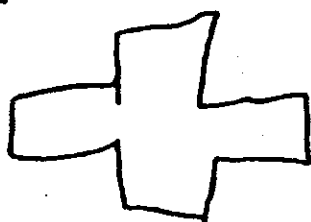
cross square

He shouted the warning



85 -
27

58



(2nd attempt)

Name W. B. Date Tested 4-8-58
 Hospital _____ Ward _____ Hospital No. _____
 Birthdate 9-23-38 Age 19 Education 13 Handedness Right
 Sex Male Occupation Student

Word Finding	<u>52</u>	W-B (Form I):	Category I II:	
Hemmon-Nelson	<u>117</u>	VIQ	<u>112</u>	<u>1 0 2 0 3 10 4 13</u>
Spokes A	<u>37"</u>	PIQ	<u>95</u>	<u>5 14 6 11 7 5</u> <u>53</u>
Spokes B	<u>65"</u>	F-S IQ	<u>105</u>	Flicker - Cps <u>29.0</u>
Trails A I II	<u>60"-6</u>	VWS	<u>56</u>	Dev <u>1.1</u>
Trails B I II	<u>91"-3</u>	PWS	<u>48</u>	TPT I II III:
Trails Total	<u>151"-9</u>	Tot WS	<u>104</u>	RH <u>7.1</u> Time <u>15.8</u>
MMPI:		Inf	<u>14</u>	LH <u>3.5</u> Mem <u>5</u>
? <u>50</u> Pd <u>58</u>		Comp	<u>12</u>	BH <u>5.3</u> Loc <u>2</u>
L <u>50</u> Mf <u>51</u>		Digit Sp	<u>7</u>	Seashore Rhythm <u>6</u>
F <u>46</u> Pa <u>50</u>		Arith	<u>9</u>	Raw Score <u>25</u>
K <u>51</u> Pt <u>40</u>		Simil	<u>14</u>	Speech Percept I II <u>8</u>
Hs <u>53</u> Sc <u>52</u>		Vocab	<u>12</u>	Tapping: RH <u>47</u> <u>47</u>
D <u>58</u> Ma <u>50</u>		P Arr	<u>13</u>	LH <u>49</u>
Hy <u>57</u>		P Comp	<u>9</u>	Time Sense - Memory <u>357.3</u>
		Bl Des	<u>9</u>	Visual <u>39.4</u>
ABC: R <u>10</u> L <u>0</u>		Obj Assem	<u>7</u>	
		Digit Sym	<u>10</u>	Impairment Index <u>0.8</u>

Aphasic Symptoms: Possible mild dystereognosis of both hands.

Report of Neuropsychological Examination

This 19-year-old boy obtained a Full-Scale Wechsler-Bellevue (Form I) IQ of 105 (Verbal IQ, 112; Performance IQ, 95). The tests of biological intelligence yielded an Impairment Index of 0.8 which is consistent with mild impairment of adaptive abilities dependent upon organic brain functions. Although the Impairment Index is 0.8, the patient's impairment is probably only mild since several tests were at a borderline level. Analysis of the pattern of test results indicates fairly consistently that the left cerebral hemisphere is more seriously damaged than the right. Nevertheless, the results imply diffuse dysfunction involving both cerebral hemispheres. Certain of the tests were done too well for us to think of an intrinsic tumor or destructive cerebral vascular lesion in either hemisphere. The results do fit quite well an impression of a moderately severe head injury (probably a closed head injury since we do not get any highly focal signs) with the left cerebral hemisphere most severely damaged. The results on the Wechsler Scale suggest that this patient was of perhaps high average intelligence but his IQ has been lowered to the normal range and in addition he has a fairly serious problem of general adaptive ability in association with impaired brain functions. Although the MMPI does not give evidence for any serious affective disturbance, it would seem likely from the test results that he will have quite a difficult problem working out a satisfactory adjustment.

RMR

Comment

The relatively long time required with the right hand as compared with the left hand on the Tactual Performance Test and the slower tapping speed with the

W. B. (Continued)

right hand are types of results that cannot be overlooked and require explanation. While these findings suggest possible impairment in the left cerebral hemisphere, the patient showed no dysphasia and actually had a higher VWS total than PWS total on the W-B. Nevertheless, the patient did rather poorly on a variety of tests relating to brain function suggesting some diffuse involvement of the cerebral hemispheres. The impression of a moderately severe closed head injury was aided substantially by failure to find concurrence between the tests largely dependent upon motor skills with the right and left hands and tests of verbal functions. Particularly in young patients with otherwise healthy brains, impaired language functions rather promptly improve. In this patient our reason for feeling that a closed head injury had been sustained was based on the indications of diffuse involvement (since this is generally the case with traumatic injury), the assumption that the Tactual Performance Test and Tapping Test were still reflecting the more serious damage in the left hemisphere, and the assumption that the damage had occurred long enough ago and was of a type that would permit recovery of possibly impaired language functions.

Neurological and Neurosurgical Summary

Symptoms: Auto accident 6 months prior to admission. He was not unconscious but was confused for about one week. Hospitalized 4 months because of fractured femur. Since accident has had headaches, tires easily, and has difficulty concentrating. Thrown from horse, 1953. Unconscious momentarily.

Signs: Neurological examination negative excepting blood pressure, 150/100.

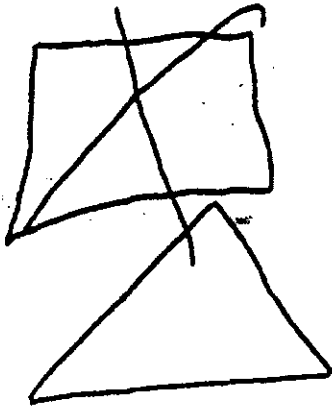
Handedness: Right.

Diagnostic EEG: Dysrhythmia Grade I, bitemporal.

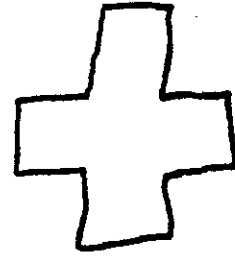

Tests: No X-rays or other studies done at this hospital.

Diagnosis: Residual brain damage, post traumatic, minimal.

1.



2.




clock square

He shouted the warning.

85
- 27

58

51



First square crossed out by patient when examiner asked him to draw it more carefully.

Name C. L. Date Tested 11-26-56
 Hospital Long Ward G Hospital No. _____
 Birthdate 6-30-10 Age 46 Education 12 Handedness Right
 Sex Female Occupation Housewife

Word Finding	-----	W-B (Form I):	Category I II:	
Herron-Nelson	-----	VIQ	106	1 0 2 1 321 422
Spokes A	-----	PIQ	105	520 618 76 88
Spokes B	-----	F-S IQ	105	Flicker - Cps
Trails A I II	<u>115"-1</u>	VWS	<u>49</u>	Dev
Trails B I II	<u>355"-1</u>	PWS	<u>41</u>	TPT I II III:
Trails Total	<u>470"-2</u>	Tot WS	<u>90</u>	RH <u>5.3</u> Time <u>17.1</u>
		Inf	<u>11</u>	LH <u>6.8</u> Mem <u>3</u>
MMPI:		Comp	<u>9</u>	BH <u>4.9</u> Loc <u>1</u>
? <u>50</u>	Pd <u>53</u>	Digit Sp	<u>13</u>	Seashore Rhythm
L <u>46</u>	Mf <u>51</u>	Arith	<u>4</u>	Raw Score <u>27</u>
F <u>58</u>	Pa <u>62</u>	Simil	<u>12</u>	Speech Percept I II <u>12</u>
K <u>55</u>	Pt <u>48</u>	Vocab	<u>12</u>	Tapping: RH <u>46</u> <u>46</u>
Hs <u>52</u>	Sc <u>49</u>	P Arr	<u>12</u>	LH <u>41</u>
D <u>51</u>	Ma <u>45</u>	P Comp	<u>10</u>	Time Sense - Memory <u>877.2</u>
Hy <u>68</u>		Bl Des	<u>7</u>	Visual <u>46.5</u>
ABC: R _____ L _____		Obj Assem	<u>6</u>	Impairment Index <u>0.9*</u>
		Digit Sym	<u>6</u>	

Aphasic Symptoms: Dysnomia, construction dyspraxia, mild right-left disorientation, paraphasia.

Report of Neuropsychological Examination

This 46-year-old woman obtained a Full-Scale Wechsler-Bellevue (Form I) IQ of 105 (Verbal IQ, 106; Performance IQ, 105). The tests of biological intelligence yielded an Impairment Index of 0.9 which is consistent with fairly severe organic impairment of adaptive abilities. The pattern of test results are difficult to correlate with a single lesion. The aphasia examination showed only very mild difficulties including a suggested naming dyspraxia and construction dyspraxia, right-left disorientation and paraphasia. These findings together with poor performances on frontal lobe indicators tend to implicate the left frontal area, although we see no indication of structural damage in the left parietal area. The right hemisphere would also seem to be involved as indicated particularly by the finding that the patient took 6.8 minutes on the Tactual Performance Test with the left hand after already having done the task in 5.3 minutes with the right hand. This finding, together with other results, suggests some structural damage in the inferior parietal and possibly posterior temporal areas. The overall results are not typical for our customary findings with intrinsic gliomas because of (1) the bilateral indications and (2) the finding that on some tests the patient did particularly well. The fairly focal nature of some of the indications, however, argues for more than one fairly discrete lesion in the brain. The results, although not diagnostic, would be perfectly compatible with bilateral metastatic involvement.

RMR

Comment

Our localization of maximal involvement in the cerebral hemispheres appears

C. L. (Continued)

to be somewhat in error in this patient (as indicated in the neurological summary), but our inference of bilateral focal involvement was correct. The report does not indicate our suspicion that the primary carcinoma was located elsewhere than the lung. Actually the primary carcinoma was in the heart with metastases to the right lung and both cerebral hemispheres. Other patients with cerebral metastases from a primary carcinoma of the lung have done very poorly on the tests, particularly if both cerebral hemispheres were involved. The relatively good performance of this patient (W-B, and Seashore Rhythm) argue against a primary carcinoma of the lung.

Neurological and Neurosurgical Summary

Symptoms: Patient had left, simple mastectomy in January, 1956, 10 months prior to admission. Diagnosis was cystosarcoma phyllodes.
Blurring of vision and severe headaches for 3 months. Also had hallucinatory visual experiences.
Syncope attacks without clonic or tonic movements, 2 months.
Carotid angiogram done at home town hospital showed displacement of the left anterior cerebral artery.
Received 3 X-ray therapy treatments and then stopped because of nausea and vomiting.

Signs: Bilateral papilledema.
Right homonymous lower quadrant visual field defect.

Handedness: Right

Diagnostic Tests: Routine laboratory tests, normal.
Bone marrow showed malignant cells.
EEG: Delta Grade II, bilateral temporal.
Dysrhythmia Grade II, generalized.
X-ray: Tumor, right lower lung.
Angiogram shows shift, left to right.
Left posterior temporal-occipital mass.
Right inferior medial temporal mass.

Treatment: Patient given X-ray therapy with some improvement. Also given TEM.

Diagnosis: Cystosarcoma phyllodes with metastases to lung and cerebrum (temporal lobes bilaterally).



JK

Clock
square

C. L.

He shouted the
warning.


25
27
—
52




1.




1.



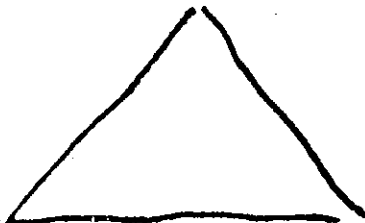2.



2.



3.



Name C. S. Date Tested 10-6-58
 Hospital _____ Ward _____ Hospital No. _____
 Birthdate 1-20-88 Age 70 Education 12 Handedness Right
 Sex Male Occupation Building and Loan Business

Word Finding		W-B (Form I):	Category I II:	
Hemmon-Nelson		VIQ	1 0 2 1 328	427
Spokes A	<u>60"</u>	PIQ	5 9 6 3 7 7	75
Spokes B	<u>113"</u>	F-S IQ	Flicker - Cps	
Trails A I II	<u>65"-6</u>	VWS	Dev	
Trails B I II	<u>211"-1</u>	PWS	TPT I II III:	
Trails Total	<u>276"-7</u>	Tot WS	RH 15.0*-3 bl.	Time 50.2*
		Inf	LH 17.0*-6 bl.	Mem 5
MMPI:		Comp	BH 18.2	Loc 2
? <u>50</u>	Pd <u>46</u>	Digit Sp	Seashore Rhythm	2
L <u>46</u>	Mf <u>51</u>	Arith	Raw Score 28	
F <u>48</u>	Pa <u>52</u>	Simil	Speech Percept I II	15
K <u>57</u>	Pt <u>57</u>	Vocab	Tapping: RH 31	31
Hs <u>76</u>	Sc <u>51</u>	P Arr	LH 40	
D <u>64</u>	Ma <u>40</u>	P Comp	Time Sense - Memory	393.6
Hy <u>68</u>		Bl Des	Visual 130.0	
		Obj Assem		
ABC: R <u>9</u>	L <u>1</u>	Digit Sym	Impairment Index	0.9*

Aphasic Symptoms: Possible mild dysnomia, mild dysgraphia, possible mild right finger dysgnosia, mild construction dyspraxia.

Report of Neuropsychological Examination

This 70-year-old man obtained a Full-Scale Wechsler-Bellevue (Form I) IQ of 99 (Verbal IQ, 109; Performance IQ, 101). The tests of biological intelligence yielded an Impairment Index of 0.9 which is consistent with moderately severe impairment of adaptive abilities dependent upon organic brain functions. Analysis of the pattern of test results suggests fairly specific impairment of function in both cerebral hemispheres. The primary symptoms of dysfunction seem, however, to come from damage in the left cerebral hemisphere that is fairly diffusely distributed. The patient was able to tap only 31 times in a ten-second period with his right hand but was able to tap 40 times with his left hand even though he is right-handed. On the Tactual Performance Test the patient also did somewhat better with his left hand than he did with his right hand. Certain findings from the aphasia examination support the hypothesis of damage in the left cerebral hemisphere. The patient has a questionable dysnomia, a mild dysgraphia, and possible mild right finger dysgnosia. In addition, the patient showed a mild constructional dyspraxia. The level of performance is sufficiently poor to raise a question of possible neoplastic disease in this patient, but the excellent performance on the Seashore Rhythm Test argues strongly against this hypothesis. The results are perfectly compatible with a hypothesis of diffuse and moderately severe cerebral vascular disease with the possibility of a cerebral vascular accident some time in the past in the left cerebral hemisphere. The present results, however, suggest a fairly static though impaired brain condition at the present time. While the damage appears probably to be maximal in the left hemisphere, we should emphasize that impairment of organic function in the right hemisphere seems almost as severe. The Minnesota Multiphasic Personality Inventory suggests the presence of marked neurotic-like symptomatology, but this is fairly much to be expected in a

C. S. (Continued)

patient of this age and with as much organic impairment of brain functions as this patient shows.

RMR

Comment

We found it a bit difficult to conclude that the left cerebral hemisphere was maximally dysfunctional in this patient because the PWS total was very much lower than the VWS total on the W-B. The signs of motor dysfunction of the right upper extremity on the Tactual Performance Test and Tapping Test together with the mild dysphasia were sufficient to require explanation. Considering that the patient's age could be responsible in part for the low PWS total on the W-B and assuming that damage to the left hemisphere occurred some time ago and was of a type that would permit some recovery of language functions, we were able to postulate that the major damage was in the left hemisphere. After these assumptions had been made, we had little difficulty in deciding on a cerebral vascular accident rather than a brain tumor since it is not at all uncommon to find evidence of fairly severe and diffuse brain dysfunction in such patients (probably associated with diffuse cerebral arteriosclerosis).

Neurological and Neurosurgical Summary

Symptoms: History of right hemiparesis and depression.
Worked up at Mayo Clinic, March 1958, with diagnosis of cerebral degeneration and insufficiency, left internal carotid artery.


Signs: Neurological examination: Mild right hemiparesis.

Diagnostic Retinal artery pressures were normal.

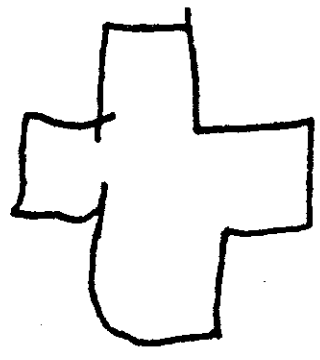
Tests: EEG: Normal for age.
No further studies done here.

Diagnosis: Cerebral vascular disease. Probable occlusion of a middle cerebral branch, left.

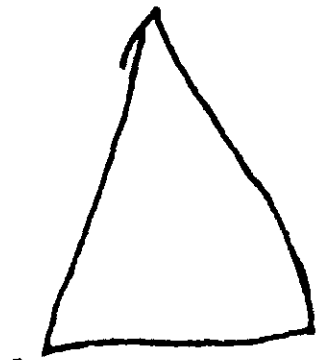
JK



1.



1.



1.

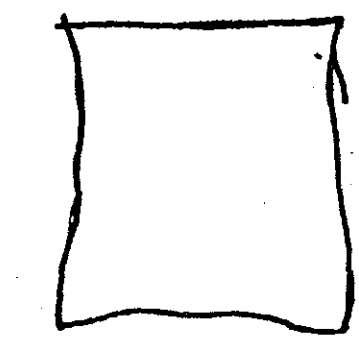
Clock
Coc
Coes

Square


He should be warning

$$\begin{array}{r} 85 \\ 27 \\ \hline 58 \end{array}$$


51



2.



2.



2.

Name V. C. Date Tested 7-17-57
 Hospital Long Ward AB Hospital No. _____
 Birthdate 1-23-01 Age 56 Education 12 Handedness Right
 Sex Male Occupation Salesman

Word Finding		W-B (Form I):	Category I II:	
Hemmon-Nelson		VIQ	109	1 0 2 0 3 30 4 -
Spokes A		PIQ	95	5 - 6 - 7 -
Spokes B		F-S IQ	101	Flicker - Cps
Trails A I II	<u>46"-8</u>	VWS	50	Dev
Trails B I II	<u>189"-1</u>	PWS	26	TPT I II III:
Trails Total	<u>235"-9</u>	Tot WS	76	RH 15.0*-5 bl.
		Inf	10	LH 15.0*-4 bl.
MMPI:		Comp	7	BH 15.0*-4 bl.
? _____ Pd _____		Digit Sp	10	Seashore Rhythm
L _____ Mf _____		Arith	16	Raw Score 11
F _____ Pa _____		Simil	7	Speech Percept I II
K _____ Pt _____		Vocab	10	Tapping: RH 44
Hs _____ Sc _____		P Arr	6	LH 26
D _____ Ma _____		P Comp	7	Time Sense - Memory
Hy _____		Bl Des	6	Visual
ABC: R _____ L _____		Obj Assem	1	
		Digit Sym	6	Impairment Index
				1.0*

Aphasic Symptoms: No apparent language deficit. Mild construction dyspraxia. Occasional failure to report stimulus to right face with left hand-right face combination and to right ear with bilateral simultaneous auditory stimulation.

Report of Neuropsychological Examination

This 56-year-old man obtained a Full-Scale Wechsler-Bellevue (Form I) IQ of 101 (Verbal IQ, 109; Performance IQ, 95). Not all of the tests of biological intelligence were completely administered because the subject was not able to finish them. The results, however, indicate an Impairment Index of 1.0 which is consistent with severe impairment of abilities dependent upon organic brain functions. Analysis of the pattern of test results suggests that the right hemisphere is more severely involved than the left hemisphere. Nevertheless, the patient would very occasionally fail to report the stimulus to the right face with simultaneous left hand-right face stimulation and occasionally failed also on the right ear with bilateral simultaneous auditory stimulation. While the general pattern of results suggests particularly severe dysfunction in the right frontal area, these latter results would suggest that the damage is diffusely distributed. It would appear most likely from our findings that the patient has severe and widely distributed impairment of cerebral function involving both hemispheres and very possibly on a vascular basis.

RMR

Comment

The results from the Tactual Performance Test and Tapping Test were reinforced by the difference between verbal and performance weighted score totals on the W-B to suggest maximal involvement of the right cerebral hemisphere. The consistently poor performance on Halstead's battery, however,

V. C. (Continued)

indicates that impairment of brain functions is of a very serious nature. The results indicating right hemisphere dysfunction would prompt one to look for evidence of a focally destructive lesion in the right hemisphere. Such evidence might consist of serious distortion of the shape of the Greek cross, finger agnosia or finger-tip number writing impairment on the left, and sensory suppression on the left. Such findings were not present. In fact, the tendency toward suppression occurred consistently on the patient's right side. This finding argues against strictly unilateral brain damage. Thus the best conclusion would appear to be one of severe and diffuse cerebral involvement such as would be associated with diffuse cerebrovascular disease.

Neurological and Neurosurgical Summary

Symptoms: Patient admitted to hospital because of angina pectoris. Neurosurgical consultation obtained because of history of fall one month prior to admission. Following this fall he had developed difficulty with memory and slowness of thought.

Signs: Patient depressed and slightly obtunded. Neurological examination otherwise negative.

Handedness: Right.

Diagnostic Tests: Lumbar Puncture: Pressure, 175; Protein, 65 and 45.

EEG: Dysrhythmia Grade I, generalized.

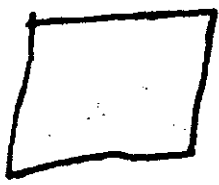
Delta Grade I, left Sylvian.

X-rays: Skull films negative.

Ventriculogram: Negative.

Diagnostic Impression: Diffuse degenerative brain disease.

JK




clock

source

He shouted the warning

$$85 - 27 = 58$$

51



Name L. B. Date Tested 11-29-55
 Hospital Long Ward _____ Hospital No. _____
 Birthdate 5-3-94 Age 61 Education 7 Handedness Right
 Sex Male Occupation Farmer

Word Finding	-----	W-B (Form I):	Category I II:	
Hemmon-Nelson	-----	VIQ	81	1 0 2 0 3 2 4 4 2 4*
Spokes A	-----	PIQ	95	5 1 9 6 2 2 7 1 3
Spokes B	-----	F-S IQ	82	Flicker - Cps
Trails A I II	<u>225"-1</u>	VWS	21	Dev
Trails B I II	<u>1392"-1*</u>	PWS	21	TPT I II III:
Trails Total	<u>1617"-2*</u>	Tot WS	42	RH <u>18.0</u> Time <u>63.1*</u>
MMPI:		Inf	3	LH <u>30.6</u> Mem
? _____ Pd	-----	Comp	5	BH <u>14.5*-2 bl.</u> Loc
L _____ Mf	-----	Digit Sp	3	Seashore Rhythm
F _____ Pa	-----	Arith	6	Raw Score
K _____ Pt	-----	Simil	4	Speech Percept I II
Hs _____ Sc	-----	Vocab	6	Tapping: RH <u>45</u> <u>45</u>
D _____ Ma	-----	P Arr	3	LH <u>42</u>
Hy _____	-----	P Comp	8	Time Sense - Memory
ABC: R _____ L _____	-----	Bl Des	3	Visual
		Obj Assem	5	
		Digit Sym	2	Impairment Index <u>1.0*</u>

Aphasic Symptoms: No language deficit. Mild left finger dysgnosia and dys-tereognosis. Suppression of stimulus to left hand with left hand-right face combination.

Report of Neuropsychological Examination

This 61-year-old man obtained a Full-Scale Wechsler-Bellevue (Form I) IQ of 82 (Verbal IQ, 81; Performance IQ, 95). The tests of biological intelligence were not all administered because the patient was so slow in his performances that insufficient time was available. On the five of these tests which were given, the patient's performance was well into the range characteristic of brain damage, yielding an extended Impairment Index of 1.0. The aphasia examination showed no pronounced defects relating to the symbolic significance of language perception or expression, but did show several findings suggesting impairment of function in the right hemisphere. A mild dystereognosis was present in the left hand together with a slight finger dysgnosia. In addition, suppression of tactile stimulation of the left hand occurred when the right face and left hand were touched simultaneously. Interpretation of the overall results for this patient clearly suggests that the right hemisphere is functioning less well than the left, with maximal involvement probably in the right parietal area. The results are difficult to interpret with respect to pattern analysis since all performances were clearly in the defective range. This suggests, however, that brain functions in this patient are generally impaired, involving both hemispheres. The signs of maximal involvement may suggest a tumor in the right parietal area. While we customarily do not find such severe impairment in cases of an extrinsic tumor, the pattern of results suggests a meningioma with fairly severe destruction of adjacent cortical tissue as a somewhat more likely possibility than a glioma. In addition to this, however, the test results suggest degenerative changes in the brain as a whole.

L. B. (Continued)

Comment

Indications of specific brain damage in the posterior part of the right hemisphere in this patient include the findings from the examination for aphasia and related symptoms (noted above) and the much poorer performance on the Tactual Performance Test with the left hand than with the right hand. We would certainly have thought that this patient had either a glioma or cerebrovascular accident in this area had the results of the W-B Scale and Tapping Test supported the other findings. However, the verbal and performance weighted score totals showed no difference and the left hand was not slow in tapping speed in comparison with the right hand. We believe that in instances in which there is a clear difference in performance with the two hands on the Tactual Performance Test but without such a difference in tapping speed, the lesion is not in the immediate vicinity of the motor strip and is of such a type that it does not impinge strongly upon the function of the motor strip even though primarily located some distance from it. We postulate that such lesions reflect themselves on the Tactual Performance Test even though they do not show up in tapping speed because of the more complex motor, sensory, and problem-solving requirements of the Tactual Performance Test. Thus, the relationships of results between the Tactual Performance Test and Tapping Test supported the hypothesis of a lesion with rather strictly focal effects probably some distance from the pre-Rolandic gyrus. Although the positive symptomatology in this patient supported the idea of a focal, lateralized lesion, the W-B Scale did not agree. We have noted empirically that the relationships between the verbal and performance parts of the W-B do not help in cases of extrinsic brain tumors. Thus, the fairly focal signs of damage in the posterior part of the right hemisphere, without support from the W-B Scale, inclined our thinking in the direction of a meningioma.

Nevertheless, it was not possible to think of the results on this patient as indicative of the customarily expected findings with a meningioma. The left finger dysgnosia and dystereognosis would customarily be viewed as indicative of actual structural involvement of the right parietal area. Suppression on the left hand of bilateral simultaneous tactile stimulation indicated structural damage even more strongly. And finally, we had not been able to test for visual suppression because of an apparent left homonymous hemianopia. Although we were unable to reconcile these findings with our hypothesis of a meningioma satisfactorily, we compromised in our report by saying that we suspected "... a meningioma with fairly severe destruction of adjacent cortical tissue as a somewhat more likely possibility than a glioma." As will be noted from the neurological summary, the lesion was a meningioma arising from within the third ventricle.

Neurological and Neurosurgical Summary

Symptoms: "Black out spells" for 7 years. Suddenly loses consciousness without knowledge of it, or memory for it, unless he is unconscious long enough to be moved. No convulsive movements reported. Most attacks are of brief duration. No incontinence or tongue biting.

Signs: Blood Pressure: 162/96. Protein, 62.
Left homonymous hemianopia, macula spared.
Right optic disc edematous.

L. B. (Continued)

Handedness: Right.

Diagnostic EEG: Delta Grade II, maximal right Sylvian.

Tests: X-ray: Skull films, calcification inferior parietal lobe, 3 cm from mid-line.

Angiogram: Bilateral carotid displacement of the right middle cerebral group of vessels, with smudging in the posterior temporal and inferior parietal.

Stony hard prostate - probably not Ca.

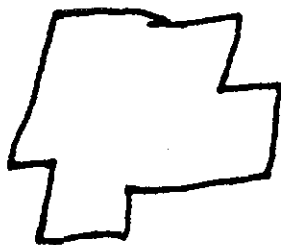
Treatment: 12-5-55: Craniotomy. Widened sulcus in the lower parietal area was incised and a large intraventricular meningioma removed. The tumor extended quite far medially and while it was being removed medially brisk bleeding was encountered and was not controlled to save patient's life. He died at 1:20 p.m.

Diagnosis: Intraventricular meningioma.

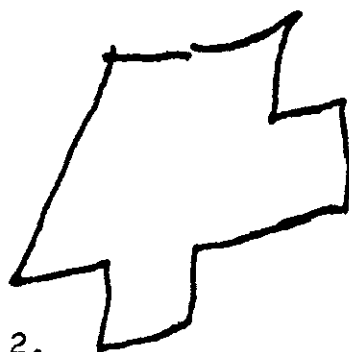
Autopsy: Incision into the brain at the parieto-temporo-occipital junctions, $6 \times 5 \times 5\frac{1}{2}$ cm. The depth of the wound ($5\frac{1}{2}$ cm.) reached to the brain stem and cerebral peduncle. Apparently the posterior cerebral artery bled, but this is not definitely stated.

RFH


PSYCHOLOGICAL TESTS ADMINISTERED BEFORE SURGERY



1.



2.



3.



clock.


85
-27

58

Trayangle
Square
Seven

~~85-27~~

Cross



Name E. H. Date Tested 9-17-58
 Hospital _____ Ward _____ Hospital No. _____
 Birthdate 4-18-01 Age 57 Education 16 Handedness right
 Sex Male Occupation Manufacturing Engineer

Word Finding	<u>50</u>	W-B (Form I):	Category I II:	
Hemmon-Nelson	<u>80</u>	VIQ	<u>129</u>	<u>1 0 2 0 324 4 9</u>
Spokes A	<u>89"</u>	PIQ	<u>104</u>	<u>5 8 6 8 7 3</u> 52
Spokes B	<u>213"</u>	F-S IQ	<u>116</u>	Flicker - Cps
Trails A I II	<u>67"-5</u>	VWS	<u>69</u>	Dev
Trails B I II	<u>119"-1</u>	PWS	<u>33</u>	TPT I II III:
Trails Total	<u>216"-6</u>	Tot WS	<u>102</u>	RH12.9* Time <u>25.2*</u>
		Inf	<u>15</u>	LH12.2*-7 6L. Mem <u>5</u>
MMPI:		Comp	<u>17</u>	BH - Loc <u>0</u>
? <u>50</u>	Pd <u>57</u>	Digit Sp	<u>10</u>	Seashore Rhythm
L <u>16</u>	Mf <u>59</u>	Arith	<u>16</u>	Raw Score <u>27</u>
F <u>53</u>	Pa <u>53</u>	Simil	<u>11</u>	Speech Percept I II
K <u>66</u>	Pt <u>79</u>	Vocab	<u>17</u>	Tapping: RH <u>45</u>
Hs <u>72</u>	Sc <u>73</u>	P Arr	<u>6</u>	LH <u>39</u>
D <u>82</u>	Ma <u>48</u>	P Comp	<u>8</u>	Time Sense - Memory
Hy <u>69</u>		Bl Des	<u>8</u>	Visual <u>71.7</u>
ABC: R <u>10</u> L <u>0</u>		Obj Assem	<u>6</u>	Impairment Index <u>0.6*</u>
		Digit Sym	<u>5</u>	

Aphasic Symptoms: None.

Report of Neuropsychological Examination

This 57-year-old man obtained a Full-Scale Wechsler-Bellevue (Form I) IQ of 116 (Verbal IQ, 129; Performance IQ, 104). The tests of biological intelligence yielded an Impairment Index of 0.6 which is consistent with mild to moderate impairment of adaptive abilities dependent upon organic brain functions. Analysis of the pattern of test results gives several findings to suggest that the right hemisphere functions less well than the left hemisphere. The patient performed considerably poorer with his left hand on the Tactual Performance Test than he had with his right hand although it was done first with his right hand. In addition, tapping speed with the left hand is perhaps a bit slow as compared with the right hand. Even considering the patient's age, the results on the Wechsler Scale also support the hypothesis of impaired function in the right hemisphere because the performance part of the test was done so much more poorly than the verbal part. No aphasia symptoms were present nor was any evidence of suppression with bilateral simultaneous stimulation found. The patient also failed to show any finger agnosia on either hand. None of the results were sufficiently poorly done and certain of the tests were well enough done to argue quite strongly against a hypothesis of an intrinsic cerebral tumor. Vascular damage also seems to be an unlikely possibility since certain of the tests were done so well. Nevertheless, the posterior part of the right hemisphere clearly appears to be more dysfunctional than the rest of the cerebral hemispheres. Our best conclusion would be that this lesion is relatively static or at best slowly developing rather than acute in onset or rapidly destroying brain function. The results suggest that this lesion is not strictly focal but it does seem to involve the right temporal region more than other areas. The findings on this patient could be compatible with the effects of a head injury, but the findings are not sufficiently specific to rule out other possibilities.

E. H. (Continued)

Comment

Localization of the area of maximal involvement (right temporal area) was relatively easy in this patient. The Tactual Performance Test and Tapping Test suggested that the right hemisphere was dysfunctional. Since the Tactual Performance Test gave by far the stronger indication, we felt that the lesion could be some distance from the motor strip. Picture Arrangement gave some help in implicating the right temporal area and the absence of tactile perceptual losses in the left hand argued against any specific right parietal damage. Some of the results were extremely unusual in consideration of the fact that the patient had a glioma. We would have expected to get a consistently poorer performance on the tests generally as well as some positive findings of suppression with bilateral simultaneous sensory stimulation. However, histological examination of sections of the tumor indicate that it is an extremely slow-growing tumor. Retrospectively, we cannot legitimately change our conclusion in the report that the results look like the possible residual effects of head trauma and must accept these results as an important illustration of the limitations of our procedures.

Neurological and Neurosurgical Summary

History: 11-10-54 patient had his first generalized seizure. No other symptoms.

Rheumatic fever and cardiac lesion, age 12.

Physical and neurological examination, negative.

EEG: Normal

X-rays: Skull and chest films normal.

Discharged on Dilantin and Serpasil.

Admitted to another local hospital in 1955 because of right-sided seizures. Pneumoencephalogram reported to show left cortical atrophy with enlarged ventricle on that side.

Admitted to Long Hospital, 3-2-56 to 3-10-56. Series of five right-sided seizures the morning of admission. Seizures began in right forearm. No other symptoms.

Physical and neurological examination negative after recovery from post seizure stupor.

EEG: Dysrhythmia Grade I, left Sylvian.

Skull film negative.

Discharged on anticonvulsants.

EEG: 7-30-58, Dysrhythmia Grade II, right Sylvian.

Symptoms: Readmitted to Long Hospital, 10-15-58 to 11-8-58. Increasing frequency of his seizures, up to 90 per month. Seizures start in right arm spread to right face then to left arm. Legs not involved.

Signs: Physical and neurological examination: Mentation slow, examination otherwise negative.

Handedness: Right.

Diagnostic Tests: EEG: Delta Grade II, right temporal area.

Angiogram: Showed mass right mid-temporal area.

E. H. (Continued)

Treatment: 10-24-58: Craniotomy. Tumor removed from right mid-temporal lobe at depth of 3 cm. P₃₂ used for localization during surgery. 2 X 3 cm. area removed. Temporal lobectomy not done. No pressure.

Postoperative Course: Postoperative course uneventful. No seizures postoperatively.

Diagnosis: Glioma, right mid-temporal area.

JK

PSYCHOLOGICAL TESTS ADMINISTERED BEFORE SURGERY

Name V. S. Date Tested 6-10-57
 Hospital Long Ward AB Hospital No. _____
 Birthdate 11-16-01 Age 56 Education 8 Handedness Right
 Sex Female Occupation Housewife

Word Finding		W-B (Form I):	Category I II:	
Hemmon-Nelson	<u>61</u>	VIQ	<u>89</u>	<u>1 0 2 2 328 430</u>
Spokes A		PIQ	<u>114</u>	<u>513 68 75 86</u>
Spokes B		F-S IQ	<u>99</u>	Flicker - Cps <u>21.7</u>
Trails A I II	<u>22"-10</u>	VWS	<u>30</u>	Dev <u>1.0</u>
Trails B I II	<u>22 1/2"-1</u>	PWS	<u>43</u>	TPT I II III:
Trails Total	<u>246"-11</u>	Tot WS	<u>73</u>	RH <u>15.0</u> *-4 bl. Time <u>38.8*</u>
		Inf	<u>10</u>	LH <u>15.7</u> Mem <u>5</u>
MMPI:		Comp	<u>12</u>	BH <u>8.1</u> Loc <u>1</u>
? _____ Pd _____		Digit Sp	<u>0</u> ✓	Seashore Rhythm <u>10</u>
L _____ Mf _____		Arith	<u>0</u> ✓	Raw Score <u>19</u>
F _____ Pa _____		Simil	<u>8</u>	Speech Percept I II <u>24</u>
K _____ Pt _____		Vocab	<u>11</u>	Tapping: RH <u>47</u> <u>47</u>
Hs _____ Sc _____		P Arr	<u>8</u>	LH <u>44</u>
D _____ Ma _____		P Comp	<u>9</u>	Time Sense - Memory <u>211.8</u>
Hy _____		Bl Des	<u>10</u>	Visual <u>287.9</u>
		Obj Assem	<u>11</u>	
ABC: R _____ L _____		Digit Sym	<u>5</u>	Impairment Index <u>0.7</u>

Aphasic Symptoms: Dysnomia, dyslexia, visual letter dysgnosia, agraphia, auditory verbal dysgnosia, spelling apraxia, right-left disorientation, mild body agnosia, dystereognosis of right hand, finger dysgnosia of right hand, finger-tip number writing loss on right hand, suppression on right of all combinations of tactile stimulation, suppression on right with bilateral auditory stimulation.

Report of Neuropsychological Examination

This 56-year-old woman obtained a Full-Scale Wechsler-Bellevue (Form I) IQ of 99 (Verbal IQ, 89; Performance IQ, 114). The tests of biological intelligence yielded an Impairment Index of 0.7, but the only tests that failed to contribute to the Impairment Index are ones that are relatively insensitive to brain damage. Evaluation of her performances shows consistent and severe impairment of abilities dependent upon organic brain functions. Examination for aphasia revealed a wide variety of symptoms including: dysnomia, dyslexia, visual letter dysgnosia, agraphia, auditory verbal dysgnosia, spelling apraxia, right-left disorientation and mild body agnosia. In addition the patient showed dystereognosis of the right hand and finger dysgnosia and finger-tip number writing loss on the right hand. Bilateral simultaneous tactile stimulation revealed suppression on the right in all combinations of hand and/or face stimulations. Suppression of the stimulus to the right ear with bilateral simultaneous auditory stimulation did not occur in each instance but clearly was present. Nevertheless, the patient showed no tendency to suppress bilateral simultaneous visual stimulation.

The test results are consistent in indicating serious damage in the left hemisphere but show no structural involvement of the right hemisphere. The severity of the impairment is consistent with our customary findings in patients with rapidly growing intrinsic tumors or severely destructive cerebral vascular

V. S. (Continued)

accidents. Differentiation of these two conditions is difficult from our test results. In this patient tapping speed was faster with the right hand than with the left hand in spite of the evidence of involvement of the left hemisphere. This finding inclines our conclusion toward an infiltrating tumor rather than a CVA. The severity and range of psychological impairment implicates the frontal, parietal and temporal areas of the left hemisphere, but infer that the lesion is located structurally primarily in the left frontal lobe and extending back to include the anterior parietal and perhaps anterior temporal area.

RMR

Comment

This patient had a glioblastoma multiforme principally in the left parietal area so our inference in the report above that the lesion was located principally in the left frontal area is clearly in error. A detailed review of the test results indicated that our error in localization was due less to the test results themselves than to our interpretation of them. The comparative performance of the two hands on the Tactual Performance Test and Tapping Test shows that the patient's performance with her right hand was much better on the Tapping Test than on the Tactual Performance Test. This finding should have pushed the localization away from the motor strip. Also the presence of tactile suppression on the right as well as finger dysgnosia, dystereognosis, and fingertip number writing recognition impairment on the right hand all presented positive evidence for parietal damage. Probably most important for inferring a more posterior location, however, were the pronounced visual and auditory (receptive) components of the patient's dysphasia. The patient had great difficulty understanding spoken language correctly and was unable to read without gross errors. In some instances she was not even able correctly to identify individual letters of the alphabet. Our mistake in localization was probably due to the fact that we were impressed by the absence of visual suppression and a right homonymous hemianopsia. Later studies, however, have suggested that visual suppression rarely seems to occur with lesions of the left hemisphere, but we did not know this at the time the report was written. This case should alert us to weigh carefully the possible disadvantage that may be associated with basing our inferences on negative rather than positive findings.

The results for this patient made the differentiation between a tumor and cerebrovascular accident fairly easy. No specifically positive findings of damage in the right hemisphere were present and more important, a cerebrovascular accident causing the marked dysphasia that this patient demonstrated should also have impaired performance with the right hand on the Tapping Test. Thus, the fairly distinct lateralization of dysfunction to the left hemisphere argued that the lesion was an intrinsic tumor.

Neurological and Neurosurgical Summary

Symptoms: Two months prior to admission patient began to make mistakes in her bookkeeping.
One month prior to admission developed some difficulty with writing and some dysphasia.
Progressive confusion, 2 weeks.

V. S. (Continued)

Signs: Aphasia.
Right hemihypesthesia.
Stereognosis and finger writing poor bilaterally.
Motor functions adequate bilaterally.

Handedness: Right.

Diagnostic X-rays: Skull films negative.
Tests: Angiogram: Left parietal mass.

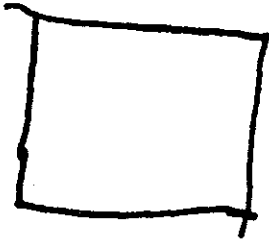
Treatment: 6-17-57: Craniotomy. Partial removal of glioblastoma, left parietal area.

Postoperative Patient developed right-sided seizures and increasing hemi-
Course: paresis and aphasia. Wound reopened on 7/20/57. Brain was edematous. Dura left open and bone flap left free. Improved slowly but complete paralysis of right upper extremity remained. Some function was present in the right lower extremity. Marked aphasia and perseveration. Treated with X-ray therapy. Discharged on anticonvulsants. Patient died at another hospital, 11-20-57.

Diagnosis: Glioblastoma multiforme, left parietal area.

JK


NEUROLOGICAL TESTS ADMINISTERED BY DR. J. K. BERRY



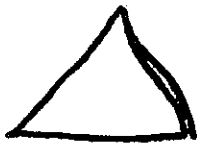
He

cho

(Attempt to write, "HE SHOUTED THE WARNING.")



$$\begin{array}{r} 85 \\ 27 \\ \hline 58 \end{array}$$



triple

trick

(Attempt to write, "WATCH")

time

so

(Attempt to write, "TIME CLOCK")

square

Name G. Y. Date Tested 10-21-54
 Hospital Veterans Ward _____ Hospital No. _____
 Birthdate 11-2-22 Age 31 Education 12 Handedness Right
 Sex Male Occupation Car Salesman and Embalmer

Word Finding		W-B (Form I):	Category I II:	
Herron-Nelson	<u>86</u>	VIQ	<u>97</u>	<u>1 0 2 0 3 2 1 4 8</u>
Spokes A		PIQ	<u>98</u>	<u>5 1 9 6 1 6 7 4</u> <u>68</u>
Spokes B		F-S IQ	<u>98</u>	Flicker - Cps
Trails A I II	<u>58"-7</u>	VWS	<u>44</u>	Dev
Trails B I II	<u>101"-2</u>	PWS	<u>44</u>	TPT I II III:
Trails Total	<u>159"-9</u>	Tot WS	<u>88</u>	RH <u>8.1</u> Time <u>23.2</u>
		Inf	<u>10</u>	LH <u>10.1</u> Mem <u>5</u>
MMPI:		Comp	<u>8</u>	BH <u>5.0</u> Loc <u>1</u>
? <u>61</u> Pd <u>63</u>		Digit Sp	<u>6</u>	Seashore Rhythm
L <u>53</u> Mf <u>56</u>		Arith	<u>9</u>	Raw Score <u>20</u>
F <u>58</u> Pa <u>50</u>		Simil	<u>11</u>	Speech Percept I II <u>13</u>
K <u>48</u> Pt <u>60</u>		Vocab	<u>8</u>	Tapping: RH <u>62</u> <u>62</u>
Hs <u>70</u> Sc <u>50</u>		P Arr	<u>4</u>	LH <u>37</u>
D <u>72</u> Ma <u>38</u>		P Comp	<u>12</u>	Time Sense - Memory <u>200.6</u>
Hy <u>67</u>		Bl Des	<u>6</u>	Visual <u>60.3</u>
ABC: R <u>0</u> L <u>10</u>		Obj Assem	<u>12</u>	Impairment Index <u>0.8*</u>
		Digit Sym	<u>10</u>	

Aphasic Symptoms: None.

Report of Neuropsychological Examination

This 31-year-old man obtained a Full-Scale Wechsler-Bellevue (Form I) IQ of 98 (Verbal IQ, 97; Performance IQ, 98). The measures of biological intelligence yielded an Impairment Index of 0.8, which is well within the range characteristic of organic brain damage. The findings with respect to lateralizing significance consistently indicate that the right hemisphere is functioning more poorly than the left. Analysis of the pattern of impaired functioning indicates the pattern to be a modified posterior-parietal as well as a modified anterior-frontal one. This suggests two possibilities: (1) that the lesion may be diffuse involving both of these areas, or (2) that the lesion may be focal and located in the anterior temporal region (since this area seems to give modifications of both parietal and frontal patterns). It seems somewhat more likely from our results that the lesion is focal, has damaged the brain tissue causing rather widespread functional effects, and is located structurally in the anterior temporal region.

RMR

Comment

The Tactual Performance Test and Tapping Test both give strong indications that the left hand does not function as well as it should with relation to the right hand. The Picture Arrangement subtest of the W-B Scale suggests maximal damage in the right temporal area, but Block Design also was rather poorly done (suggesting the hypothesis of posterior right temporal or right parietal damage) and the slow tapping with the left hand suggests that the posterior part of the right frontal lobe is also impaired in its function. So far we have a lesion that could well be an intrinsic tumor in the right temporal area

G. Y. (Continued)

exerting the rather widespread dysfunctional effects to adjacent areas that commonly occur with such lesions. Two factors argue against a conclusion that the lesion is either neoplastic or vascular in nature. First, the verbal and performance weighted score totals on the W-B Scale are equal. With lesions of the right hemisphere particularly, the performance total is lowered in cases of tumors and cerebrovascular accidents. Secondly, Trails B was performed in 101" which is too fast to make either of these diagnostic possibilities likely. The effects of the lesion are too widely distributed (frontal, temporal, parietal) to make a meningioma a likely possibility and, more important, the patient is severely enough impaired generally to suggest actual structural damage of brain tissue. I do not know if we could have called the lesion a penetrating head injury at present, but the test results do seem to fit the expected description of this condition fairly well.

Neurological and Neurosurgical Summary

- 9-26-54: Admitted to Indianapolis General Hospital. "Beaten up" 2 days previously and found confused in room in local hotel. Confused, very little memory for previous several days, restless. Severe headache. Blood from right ear, old and dark. Neurological otherwise negative.
- 9-26-54: Lumbar Puncture: 6,400 wbc, 90% Polys. Pressure, 193; fluid yellow and formed pellicle. Protein 144 mg %. Sugar 45 mg %.
- 9-27-54: Laceration found just anterior to right ear with dark blood coming from it. Probe inserted several inches under scalp. Patient denied knowledge of this injury.
- 9-28-54: Improved on penicillin and sulfadiazine.
- 10-2-54: Abscess anterior to right ear drained spontaneously. No organism seen or grown.
- 10-5-54: Transferred to Indianapolis Veterans Hospital (Medical Service). Granulating area right temple only abnormal finding. CSF Pressure 160 mm fluid. 44 lymphocytes, no polys, protein 106 mgm. %.
- 10-8-54: EEG: Slow frequency high amplitude waves right Sylvian, with background of rhythmical activity, suggested subcortical destructive process, possible abscess.
- 10-13-54: Neurosurgical consult: No abnormal neurological findings. Headaches and CSF findings suggested brain abscess, right temporal. No fever.
- 10-14-54: CSF: 264 WBC, 97% lymphs. Sugar, 54. Protein, 85 mgm%.
- 10-6-54: Skull X-rays showed penetrating skull defect with indriven fragments, suggesting bullet wound. Since no history of such the diagnosis was doubted.
- 10-25-54: Carotid angiography, marked elevation of the right middle cerebral artery.

G. Y. (Continued)

11-2-54: Surgery: Thick-walled abscess removed from right temporal lobe. There was scarring between temporal muscle, bone, dura mater, and cortex, to a tract in the brain which led into the abscess. 30 cc of pus aspirated, and wall removed. No organism cultured.


11-17-54: Recovered very rapidly after surgery.

11-19-54: Discharged from hospital.

RFH

PSYCHOLOGICAL TESTS ADMINISTERED BEFORE SURGERY


He shouted the warning.



Square
Cross
Jewel



Clock



85
27

58

△
Pyramid

Name H. S. Date Tested 10-25-54
 Hospital _____ Ward _____ Hospital No. _____
 Birthdate 9-5-83 Age 71 Education 14 Handedness Right
 Sex Female Occupation Housewife

Word Finding		W-B (Form I):	Category I II:	
Herron-Nelson	<u>83</u>	VIQ	<u>114</u>	<u>1 0 2 0 3 15 4 7</u>
Spokes A		PIQ	<u>106</u>	<u>5 8 6 3 7 2</u> <u>35</u>
Spokes B		F-S IQ	<u>113</u>	Flicker - Cps
Trails A I II	<u>52"-7</u>	VWS	<u>55</u>	Dev
Trails B I II	<u>297"-1</u>	PWS	<u>42</u>	TPT I II III:
Trails Total	<u>349"-8</u>	Tot WS	<u>97</u>	RH <u>29.7</u> Time <u>58.7</u>
MMPI:		Inf	<u>15</u>	LH <u>20.0</u> Mem <u>1</u>
? _____ Pd _____		Comp	<u>15</u>	BH <u>9.0</u> Loc <u>1</u>
L _____ Mf _____		Digit Sp	<u>4</u>	Seashore Rhythm
F _____ Pa _____		Arith	<u>9</u>	Raw Score <u>21</u>
K _____ Pt _____		Simil	<u>12</u>	Speech Percept I II <u>12</u>
Hs _____ Sc _____		Vocab	<u>15</u>	Tapping: RH <u>39</u> <u>39</u>
D _____ Ma _____		P Arr	<u>6</u>	LH <u>36</u>
Hy _____		P Comp	<u>12</u>	Time Sense - Memory <u>503.7</u>
		Bl Des	<u>8</u>	Visual <u>51.9</u>
		Obj Assem	<u>10</u>	
ABC: R <u>10</u> L <u>0</u>		Digit Sym	<u>6</u>	Impairment Index <u>0.9*</u>

Aphasic Symptoms: Mild dyscalculia, dyslexia, dysgraphia, dysnomia, visual letter dysgnosia.

Report of Neuropsychological Examination

This 71-year-old woman obtained a Full-Scale Wechsler-Bellevue (Form I) IQ of 113 (Verbal IQ, 114; Performance IQ, 106). The pattern of test results suggests that her original level of psychometric intelligence was well into the superior range, but a poor performance consistent with brain damage occurred on certain of the subtests. The measures of biological intelligence yielded an Impairment Index of 0.9, which is well into the range characteristic of brain damage. The possibility that the impairment may be in part associated with advanced years must be considered, but the pattern of abilities suggests the presence of rather localized brain dysfunction. Dysphasic symptoms were found, including dyscalculia and some dyslexia, dysgraphia, dysnomia, and visual letter dysgnosia. These symptoms together with certain of the test results imply a lesion in the left hemisphere possibly involving the area around the junction of the Rolandic and Sylvian fissures. The intensity of these indications was sufficient to imply cortical damage in this area, although the difficulty may have originated with an extrinsic lesion. The test results indicate normal abstraction ability, which seems to be associated with the function of the anterior frontal lobes. Adequate ability in this respect is not consistent with our usual findings in patients with intrinsic tumors or massive cerebral vascular accidents, since damage of this type usually impairs abstraction ability substantially regardless of the structural location of the lesion. Additional positive findings occurred, however, which imply organic dysfunction of a relatively localized area in the right hemisphere. This second area involved appears to be located in the anterior-middle part of the right temporal lobe.

H. S. (Continued)

Comment

The results for this patient again illustrate the importance of dysphasic symptoms. These symptoms were not pronounced and some of them may not have been detected by an inexperienced examiner or by an examiner who was not using standard stimulus material. (The value in using standard procedures in examining for aphasia derives from the increased sensitivity the examiner develops to pathological responses as his range of experience increases). The additional test results yield little assistance in localizing the lesion in this case. The mild dysnomia and dysgraphia imply defective functioning of the posterior-inferior part of the frontal lobe. The left temporal lobe would also seem to be involved because of the receptive losses seen in the mild visual letter dysgnosia and dyslexia. Tactile symptoms that might have involved parietal function were not present. The good score on the Category Test was a big help in suggesting that the dysfunction in the left cerebral hemisphere was not the result of neoplastic or cerebrovascular disease. The results from the Picture Arrangement and Block Design subtests were interpreted as suggesting some dysfunction in the right hemisphere, but no verification of this interpretation was obtained at autopsy.

Neurological and Neurosurgical Summary

Symptoms: Convulsions, right face, 9 months.
Difficulty in writing, 9 months.
(a) Use of inappropriate words in writing.
(b) Deteriorating penmanship.

Signs: Tendon reflexes hyperactive, right extremities.
Babinski response equivocal, right.

Handedness: Right.

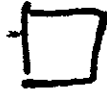Diagnostic Tests: 10-26-54: Tested for aphasia.
10-26-54: Pneumoencephalogram.

Treatment: 10-27-54: Left fronto-temporal craniotomy.
Removal of meningioma.


Diagnosis: Meningioma, left Sylvian fissure.

RFH

PSYCHOLOGICAL TESTS ADMINISTERED BEFORE SURGERY



1.



2.



triangle


check
square

cross

seven

$$85 - 27 = 58$$

$$\begin{array}{r} 27 \\ \hline 58 \end{array}$$



We started to drawing
(We started the drawing)

Name W. V. Date Tested 10-7-58
 Hospital Veterans Ward 6-S Hospital No. _____
 Birthdate 10-20-25 Age 32 Education 6 Handedness Right
 Sex Male Occupation House Painter

Word Finding	<u>33</u>	W-B (Form I):	Category I II:	
Hemion-Nelson	<u>80</u>	VIQ	<u>98</u>	1 0 2 0 3 9 4 1
Spokes A	<u>54"</u>	PIQ	<u>80</u>	5 6 6 2 7 3
Spokes B	<u>68"</u>	F-S IQ	<u>89</u>	Flicker - Cps
Trails A I II	<u>70"-5</u>	VWS	<u>45</u>	Dev
Trails B I II	<u>135"-2</u>	PWS	<u>30</u>	TPT I II III:
Trails Total	<u>205"-7</u>	Tot WS	<u>75</u>	RH <u>10.0*-2 bl.</u> Time <u>31.5*</u>
MMPI:		Inf	<u>9</u>	LH <u>10.0*-3 bl.</u> Mem <u>7</u>
? <u>50</u>	Pd <u>69</u>	Comp	<u>8</u>	BH <u>11.5*-5 bl.</u> Loc <u>2</u>
L <u>53</u>	Mf <u>45</u>	Digit Sp	<u>13</u>	Seashore Rhythm
F <u>62</u>	Pa <u>59</u>	Arith	<u>10</u>	Raw Score <u>26</u>
K <u>68</u>	Pt <u>69</u>	Simil	<u>5</u>	Speech Percept I II
Hs <u>82</u>	Sc <u>78</u>	Vocab	<u>8</u>	Tapping: RH <u>43</u> <u>43</u>
D <u>53</u>	Ma <u>50</u>	P Arr	<u>3</u>	LH <u>35</u>
Hy <u>75</u>		P Comp	<u>8</u>	Time Sense - Memory
		Bl Des	<u>7</u>	Visual <u>70.9</u>
		Obj Assem	<u>10</u>	
ABC: R <u>10</u> L <u>0</u>		Digit Sym	<u>2</u>	Impairment Index <u>0.5*</u>

Aphasic Symptoms: Visual letter and visual number dysgnosia, possible mild dysgraphia.

Report of Neuropsychological Examination

This 32-year-old man obtained a Full-Scale Wechsler-Bellevue (Form I) IQ of 89 (Verbal IQ, 98; Performance IQ, 80). The tests of biological intelligence yielded an Impairment Index of 0.5, indicating mild impairment of abilities dependent upon organic brain function. Analysis of the pattern of test results reveals that the patient has certain very bad performances particularly on the Tactual Performance Test, and certain very good performances as for example on the Category Test (score 21). The Wechsler-Bellevue subtest pattern gave a verbal weighted score of 45, performance weighted score 30. The Picture Arrangement subtest was done particularly poorly. An aphasia examination revealed visual letter and visual number dysgnosia and possible mild dysgraphia. Examination for tactile suppression gave normal results. The patient showed a tendency to suppress bilaterally when both ears were stimulated simultaneously. However, there was a tendency to suppress more often on the left than on the right ear. Examination for visual suppression gave normal results. Finger agnosia was not present, but the patient had grossly impaired perception of finger-tip number writing for the fingers of both hands. Dystereognosis was present for both hands without any substantial difference between the hands. The pattern obtained by this patient is very atypical for an intrinsic cerebral neoplasm, but would strongly suggest multiple sclerosis, although the test results by no means are diagnostic of such a condition. The Minnesota Multi-Phasic Personality Inventory suggests mild neurotic-like symptomatology.

HK

W. V. (Continued)

Comment

The test results obtained by this patient are quite typical for a large number of patients with the diagnosis of multiple sclerosis. One of the more outstanding findings in this patient is an apparent inconsistency in the test results reflected in a very poor performance on the Tactual Performance Test as compared to a fair level of performance on most of the other tests. This may be due to more severe peripheral involvement than central involvement which is seen particularly in the earlier stages of the disease. The general level of test results in this patient was fairly good. The Category Test was done very well, but the patient, nevertheless, had certain difficulties. For example, he correctly localized only two forms in his drawing following the Tactual Performance Test in spite of the fact that he worked with the blocks and the board for 31.5 minutes before the test was discontinued. The Trail Making Test, the Speech Perception Test, and the Finger Tapping Test were also in the range characteristic of brain damage. Together with an Impairment Index of 0.5, satisfactory evidence was present for a conclusion of brain damage. The relative mildness of these indications, however, was certainly inconsistent with the results on the Tactual Performance Test in which the patient placed only 2 blocks with the right hand and 3 blocks with the left hand in successive 10-minute trials. In 11.5 minutes with both hands 5 blocks were placed. On the W-B Scale there was a discrepancy between the verbal and performance weighted scores, the performance score being 15 points lower than the verbal score. This is mainly due to low scores on Digit Symbol and Picture Arrangement. The low Digit Symbol score was due to motor impairment while an impaired performance on Picture Arrangement may be associated with dysfunction in the right temporal lobe. This deficiency on Picture Arrangement is rather typical for multiple sclerosis when it occurs in a constellation such as that described above. We have often observed that a low score on Picture Arrangement is associated with lesions involving the right anterior temporal lobe. Neuropathological studies (Courville) have pointed out a tendency for plaques to occur earlier and more frequently in the area of the temporal lobes as compared to other parts of the brain. This patient tapped slightly poorer with his left hand as compared with his right. This is an additional indication of some involvement in the vicinity of the right motor strip. The performance on the aphasia test gave additional evidence for some central involvement. Mild visual letter and visual number dysgnosia were demonstrated. There were no other specific left hemisphere signs pertaining to language. The poor writing of this patient is probably entirely related to motor impairment rather than to dysgraphia. The poor copying of the figures appears also to be typical of peripheral motor involvement rather than disturbance of ability to integrate spatial relationships. Mild signs of auditory suppression bilaterally indicate bilateral temporal lobe involvement. Tactile and visual suppression are not commonly seen in multiple sclerosis. Finger dysgnosia was not present in this patient although this finding sometimes occurs for some fingers but not others in patients with multiple sclerosis. Finger-tip number writing perception was markedly impaired on the right hand, supporting the mild aphasic symptoms noted earlier. Disturbed stereognosis in both hands emphasized again the diffuse nature of the disease.

In summary, the main points contributing to the diagnosis in this case were the marked motor involvement as compared with results on the rest of the tests, the low Picture Arrangement score, and indications of mild diffuse involvement with certain abilities quite well preserved.

W. V. (Continued)

Neurological and Neurosurgical Summary

Symptoms: Ten days prior to admission patient awoke with smoky, hazy vision in the right eye. This became worse so he could barely perceive light with the right eye. Patient had a similar episode of loss of vision on left 5 years previously.

Signs: Hand movements only seen with right eye.
Left eye, 20/35.
Right pupil slightly dilated and reacted sluggishly.
10° central scotoma, left.
Neurological examination otherwise normal.

Diagnostic Tests: CSF: Protein 45.
Gold curve flat.
Serology negative.
EEG: Normal.

Treatment: Vision improved without treatment.

Diagnosis: Retrobulbar neuritis, right.
Multiple sclerosis suspected.

Symptoms: Readmitted 9-26-58 to 10-29-58 because of progressive weakness and numbness of both lower extremities, 5 days duration. The day of admission he developed difficulty using his right hand.

Signs: Neurological examination: Temporal pallor of discs.
Bilateral mild weakness, both lower extremities.
Vague sensory loss below T4.
Nystagmus.
Mild dysmetria, right upper extremity.
Adiokokinesia, right upper extremity.

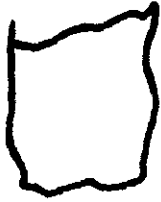

Handedness: Right.

Diagnostic Tests: EEG: Normal.
X-rays: Spine and skull films normal.

Treatment: Treated with cortisone and physical therapy and improved.

Diagnosis: Multiple sclerosis.

JK




Close

he shorted the morning

square

56'
27
58



Name J. S. Date Tested 2-23-56
 Hospital Long Ward D Hospital No. _____
 Birthdate 6-26-07 Age 48 Education 3 Handedness Left
 Sex Male Occupation Construction worker

Word Finding	-----	W-B (Form I):	Category I II:	
Herron-Nelson	-----	VIQ	93	1 0 2 0 3 9 4 9
Spokes A	-----	PIQ	97	5 17 6 11 7 3
Spokes B	-----	F-S IQ	94	-----
Trails A I II	<u>54"-7</u>	VWS	37	Flicker - Cps
Trails B I II	<u>113"-2</u>	PWS	34	-----
Trails Total	<u>167"-9</u>	Tot WS	71	Dev
		Inf	10	TPT I II III:
MMPI:		Comp	11	PHRH ₁ 8.2
? <u>50</u>	Pd <u>74</u>	Digit Sp	7	PHRH ₂ 7.0
L <u>43</u>	Mf <u>47</u>	Arith	3	PHRH ₃ 6.6
F <u>53</u>	Pa <u>47</u>	Simil	6	Seashore Rhythm
K <u>59</u>	Pt <u>56</u>	Vocab	6	Raw Score 25
Hs <u>85</u>	Sc <u>67</u>	P Arr	6	Speech Percept I II
D <u>60</u>	Ma <u>68</u>	P Comp	4	Tapping: RH 36
Hy <u>73</u>		Bl Des	6	LH 28
		Obj Assem	12	Time Sense - Memory
ABC: R <u>0</u>	L <u>10</u>	Digit Sym	6	Visual 109.6
				Impairment Index
				0.6

Aphasic Symptoms: No language deficit. Astereognosis and finger agnosia of left hand, suppression of tactile stimulus to left hand when given in combination with either right hand or right face.

Report of Neuropsychological Examination

This 48-year-old man obtained a Full-Scale Wechsler-Bellevue (Form I) IQ of 94 (Verbal IQ, 93; Performance IQ, 97). The tests of biological intelligence yielded an Impairment Index of 0.6 with three additional tests barely failing to contribute to a higher Impairment Index. This result is consistent with brain damage resulting in moderately severe impairment of the patient's adaptive abilities. Analysis of the pattern of test results indicates that the right hemisphere is functioning considerably less well than the left. The aphasia examination indicated an astereognosis of the left hand and suppression of the stimulus to the left hand with bilateral simultaneous stimulation of either the right hand or right face and the left hand. In addition, the patient sometimes suppressed the stimulus to the left face when the right hand and left face were simultaneously touched. Other test results, together with these findings, suggest damage in the right temporo-parietal area, but performances on certain tests were better than those usually obtained in patients with intrinsic tumors, except possibly for very slowly growing ones. Neither are the results consistent with our usual findings from patients with extrinsic tumors in the area of involvement, but damage of some kind would appear to be present in the right temporo-parietal area. Personality tests indicate the presence of moderately severe affective disturbances.

RMR

Comment

The tactile perceptual disorders noted above provide the principal basis

J. S. (Continued)

for inferring maximal damage in the right cerebral hemisphere. The Tapping Test was of some assistance, since the left hand was slow in comparison with the right hand even though both hands were fairly slow. The tactile suppression finding alerts one to the possibility of an intrinsic tumor or cerebrovascular accident in the right hemisphere, but several other findings present a strong argument against drawing this conclusion. First, the patient's general ability level is too good on several tests to make either of these possibilities likely (Category, Trails, Speech Perception, and Seashore Rhythm). A more convincing argument against either of these conclusions, however, is the small difference between the verbal and performance totals of the W-B Scale. A tumor or cerebrovascular accident in the right hemisphere causing suppression phenomena should certainly have lowered the performance subtests to a greater extent. The possibility of an extrinsic tumor was argued against because the area of specific dysfunction seemed a little too extensive and because the symptoms of brain damage were too severe. In spite of the tactile suppression, the lesion appeared to be relatively static in nature (because of the reasons listed above that argue against an acutely destructive or rapidly progressive lesion).

Neurological and Neurosurgical Summary

Symptoms: Patient had his first seizure 3 weeks prior to admission. Seizure started with numbness and jumping of left little finger. It progressed up the arm and down the left side into his leg. He then lost consciousness. Two other seizures have occurred since, starting in the left sternocleidomastoid muscle without loss of consciousness.
Compound depressed skull fracture, right parietal-temporal region, 1939, unconscious $1\frac{1}{2}$ hours.
Scalp wound left parietal area, 1949.

Signs: 3 X 5 cm. palpable skull defect, right superior temporal area.
Neurological examination: Astereognosis left hand.
Inability to identify numbers written on left hand.
Position sense impaired in left hand.
Two point discrimination absent in left hand.

Handedness: Left.

Diagnostic Tests: EEG: Delta Grade I, right parietal-occipital area.
Skull films: Skull defect, posterior parietal area.

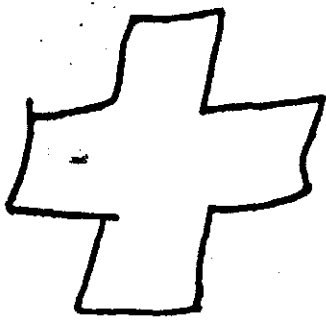

Treatment: Craniectomy with removal of meningo-cortical scar and depressed bone fragments. Cranioplasty. Pathology report: chronic meningitis, brain cicatrix.

Postoperative Course: Uneventful recovery.
Discharged on anticonvulsant medication.

Diagnosis: Meningo-cortical scar, right parietal area.

JK

PSYCHOLOGICAL TESTS ADMINISTERED BEFORE SURGERY




Clock

Square
Seven

He should the wearing

$$85 - 27 =$$

$$\begin{array}{r} 27 \\ \underline{58} \end{array}$$



Name G. H. Date Tested 10-24-55
 Hospital Veterans Ward _____ Hospital No. _____
 Birthdate 2-17-21 Age 34 Education 9 Handedness Right
 Sex Male Occupation Factory worker

Word Finding		W-B (Form I):	Category I II:	
Herron-Nelson	<u>78</u>	VIQ	<u>98</u>	<u>1 0 2 0 3 1 3 4 5</u>
Spokes A		PIQ	<u>104</u>	<u>5 5 6 2 7 6</u>
Spokes B		F-S IQ	<u>102</u>	Flicker - Cps
Trails A I II	<u>30"-10</u>	WVS	<u>44</u>	Dev
Trails B I II	<u>120"-2</u>	PWS	<u>46</u>	TPT I II III:
Trails Total	<u>150"-12</u>	Tot WS	<u>90</u>	RH <u>14.2</u> Time
		Inf	<u>6</u>	LH <u>6.4</u> Mem
MMPI:		Comp	<u>11</u>	BH <u>4.0</u> Loc
? <u>50</u>	Pd <u>64</u>	Digit Sp	<u>6</u>	Seashore Rhythm
L <u>50</u>	Mf <u>53</u>	Arith	<u>9</u>	Raw Score <u>20</u>
F <u>50</u>	Pa <u>39</u>	Simil	<u>12</u>	Speech Percept I II
K <u>68</u>	Pt <u>60</u>	Vocab	<u>6</u>	Tapping: RH <u>47</u>
Hs <u>65</u>	Sc <u>55</u>	P Arr	<u>7</u>	LH <u>49</u>
D <u>68</u>	Ma <u>53</u>	P Comp	<u>9</u>	Time Sense - Memory
Hy <u>64</u>		Bl Des	<u>13</u>	Visual <u>31.1</u>
		Obj Assem	<u>11</u>	
ABC: R <u>7</u>	L <u>3</u>	Digit Sym	<u>6</u>	Impairment Index
				<u>0.6</u>

Aphasic Symptoms: Spelling dyspraxia. Probably a mild loss in finger-tip number writing perception on the right as compared with the left hand.

Report of Neuropsychological Examination

This 34-year-old man obtained a Full-Scale Wechsler-Bellevue (Form I) IQ of 102 (Verbal IQ, 98; Performance IQ, 104). The tests of biological intelligence yielded an Impairment Index of 0.6 which is just within the range suggestive of organic impairment of brain functions. Analysis of the pattern of test results consistently suggests that the left hemisphere is functioning less well than the right. The right hemisphere seems to be within normal limits. The results do not suggest the presence of an expanding intrinsic lesion in the left hemisphere and are not quite what we would expect from a meningioma. The results do suggest, however, that the left anterior temporal lobe is primarily involved. Tests of affective functions do not indicate any disturbances which may not be accounted for on the basis of organic brain dysfunction.

RMR

Comment

The measures we presently consider to be maximally sensitive to organic impairment of brain functions (Impairment Index, Category, Trails, and Localization on the Tactual Performance Test) were in the brain-damaged range except for the Category Test. The results, therefore, pointed rather strongly to organically impaired brain functions but, nevertheless, the patient was not severely impaired on any measures. The score on the Category Test, particularly, suggested that the lesion was not neoplastic or cerebrovascular in nature. Absence of pronounced lateralizing indicators also was a factor in this conclusion. However, the left cerebral hemisphere definitely seemed more dysfunctional than

G. H. (Continued)

did the right. The patient required considerably more time with the right hand than the left on the Tactual Performance Test and also was not able to tap as fast with his right hand as with his left hand. The comparison of verbal and performance weighted scores on the W-B Scale gave no strong support to the hypothesis of left cerebral damage. We should expect such support, however, from neoplastic or cerebral vascular lesions and a conclusion along these lines is already contraindicated. The mild spelling dyspraxia and finger-tip number writing loss on the right hand do support the hypothesis of maximally impaired cerebral function in the left hemisphere. These various positive results for left cerebral involvement seem to extend the area of dysfunction from the posterior part of the frontal lobe (Tapping Test) to include the temporal lobe (spelling dyspraxia) and parietal area (finger-tip number writing loss). The possibility of a meningioma was contraindicated because the area of involvement seemed too widespread and the signs of brain dysfunction argued a bit too strongly for some kind of actual structural involvement. Possibly the rather poor cross and key should have alerted us to a type of pathology that was to some extent diffuse in its effects, but we probably could not have expected to identify the lesion as an arteriovenous malformation.

Neurological and Neurosurgical Summary

Symptoms: Patient admitted to hospital because of a grand mal seizure, his first, two days prior to admission.
No other symptoms.
Episodes of severe headache and stiff neck in 1951.

Signs: Neurological examination negative.

Handedness: Right

Diagnostic Tests: EEG: Dysrhythmia Grade I, bitemporal, maximal left Sylvian.

Metrazol induced right-sided seizure.

Skull films negative.


Angiogram: Arteriovenous malformation, left temporal-parietal area. Main feeding vessel was the left middle cerebral artery.

Pneumoencephalogram: Slight shift to right.

Treatment: Lesion felt to be inoperable because of location.

Diagnosis: Arteriovenous malformation, left temporal-parietal area.

JK




Triangle clack

G. H.

square
cross
seven

85
27

58



he started the morning

Name P. H. Date Tested 10-26-56
 Hospital Veterans Ward 5-5 Hospital No. _____
 Birthdate 8-22-89 Age 67 Education 16 Handedness Right
 Sex Male Occupation Salesman

Word Finding	W-B (Form I):	Category I II:	
Hemmon-Nelson	VIQ <u>104</u>	1 3 2 15 3 30 4 -	
Spokes A	PIQ <u>88</u>	5 - 6 - 7 -	
Spokes B	F-S IQ <u>90</u>	Flicker - Cps	
Trails A I II <u>120"-1</u>	VWS <u>43</u>	Dev	
Trails B I II <u>227"-1*</u>	PWS <u>9</u>	TPT I II III:	
Trails Total <u>347"-2*</u>	Tot WS <u>52</u>	RH 10.0*-1 bl.	Time -
	Inf <u>13</u>	LH 10.0*-0 bl.	Mem -
MMPI:	Comp <u>11</u>	BH 8.0*-0 bl.	Loc -
? _____ Pd _____	Digit Sp <u>7</u>	Seashore Rhythm	<u>10</u>
L _____ Mf _____	Arith <u>4</u>	Raw Score <u>15</u>	
F _____ Pa _____	Simil <u>8</u>	Speech Percept I II	<u>34</u>
K _____ Pt _____	Vocab <u>13</u>	Tapping: RH <u>52</u>	<u>52</u>
Hs _____ Sc _____	P Arr <u>3</u>	LH <u>37</u>	
D _____ Ma _____	P Comp <u>4</u>	Time Sense - Memory	<u>1076.5</u>
Hy _____	P Des <u>1</u>	Visual <u>251.6</u>	
ABC: R _____ L _____	Obj Assem <u>0</u>	Impairment Index	<u>0.9*</u>
	Digit Sym <u>1</u>		

Aphasic Symptoms: No language deficits. Right-left disorientation, construction apraxia, tactile and auditory suppression on left, mild left finger dysgnosia.

Report of Neuropsychological Examination

This 67-year-old man obtained a Full-Scale Wechsler-Bellevue (Form I) IQ of 90 (Verbal IQ, 104; Performance IQ, 88). The tests of biological intelligence yielded an Impairment Index of 0.9 indicating severe impairment of abilities dependent upon organic brain function. Analysis of the pattern of test results indicates severe damage to the middle and posterior part of the right hemisphere. An aphasia examination yielded the following results: no abnormalities with respect to language function, some degree of right-left disorientation, and rather marked construction apraxia (inability to integrate spatial relationships). Examination for tactile stimulation revealed suppression of stimuli to the left when the right hand-left hand and right face-left hand were stimulated simultaneously. Suppression of auditory stimuli to the left ear would also occur with bilateral stimulation. Examination for visual suppression was not done because of the patient's left field defect. There was no dysterognosis, very mild finger agnosia of the left hand, and inability to perceive number writing on the finger tips of both hands. The overall pattern of this patient's test results is indicative of a rapid-growing, infiltrating lesion in the posterior part of the right hemisphere, although another less likely possibility might be a vascular accident in the same area.

HK

Comment

This patient presents a test pattern that is fairly typical of rapidly developing and destructive lesions in the right hemisphere. The Category Test

P. H. (Continued)

had to be discontinued and the patient was unable to make any progress on the Tactual Performance Test. After 10 minutes with the right hand only 1 block was placed. On the other trials the patient was unable to place any blocks. Typical of severely destructive lesions are low performances on both the Seashore Rhythm Test and the Speech Perception Test. Even with this type of lesion in the right hemisphere an error score of 34 on Speech Perception is not unusual. In this patient's results, however, this score does not stand out as an exceptionally poor performance. The Finger Tapping Test showed clear impairment of performance with the left hand while results with the right hand were on a fairly adequate level. This pattern then indicates that the right hemisphere may be the site of the lesion in this patient. This impression is substantiated by the pattern on the W-B Scale with a verbal weighted score of 43 versus a performance weighted score of 9. The aphasia examination did not reveal any specific left hemisphere symptoms, but the patient demonstrated severe constructional apraxia (spatial distortion). Tactile suppression was present for the left hand in the right hand-left hand and right face-left hand combinations. Tendency to suppress auditory stimuli to the left was also noted. Visual suppression was not examined since a left homonymous hemianopsia was demonstrated. The Trail Making Test was performed very poorly and on a level compatible with a severe brain lesion.

In summary the most helpful findings in this patient were signs of severe organic deterioration with striking impairment on the performance part of the W-B Scale, motor impairment which was more severe for the Tactual Performance Test, and sensory suppression to the left. The much poorer performance on the Tactual Performance Test as compared with finger tapping, together with the suppression phenomena, would place the lesion posterior to the central sulcus. The generally poor level of the results considered in relation to the discrepancy between the verbal and performance weighted scores indicates strongly an intrinsic destructive lesion. In view of no aphasia and good finger tapping speed for the right hand the possibility of a vascular accident seemed less likely than a tumor.

Neurological and Neurosurgical Summary

Symptoms: Three months prior to admission patient complained of dizziness, fatigue and blurring of vision. Had glasses changed 3 times in past 3 months.

Three weeks prior to admission he developed severe frontal headaches. During the week prior to admission he developed left sided weakness and numbness.

Signs: Physical examination: Normal.
Neurological examination: Sluggish and apathetic.
Discs flat.
Left homonymous hemianopsia.
Left central facial paresis.
Left spastic hemiparesis involving upper extremity more than lower.
Left hemihypalgesia.
Reflexes increased on left.
Babinski positive, left.
Sensory suppression, left; astereognosis, left; finger agnosia, left.
Acalculia.

P. H. (Continued)

Handedness: Right.

Diagnostic Tests: CSF: Protein, 120 mgm %, 100% lymphs, 190 WBC, sugar, 54.
Serology negative.

EEG: Delta Grade III, right temporal-frontal-parietal area.
Dysrhythmia Grade II, generalized, maximal right.
Asymmetry Grade I.

X-ray: Skull films, negative.

Angiogram: Right occipital-parietal-temporal mass.

Incidental finding: Aneurysm of internal carotid, right.

Treatment: 9-28-56: Craniotomy. Occipital lobectomy. Additional tumor also removed from parietal area.


Postoperative Course: Hemiparesis cleared almost completely one week postoperatively.
Astereognosis cleared. Still had marked dressing apraxia.
Considerable difficulty telling time. Given X-ray therapy.

Diagnosis: Astrocytoma Grade III, right parietal-temporal-occipital area.


JK

PSYCHOLOGICAL TESTS ADMINISTERED AFTER SURGERY

he shouted the warning

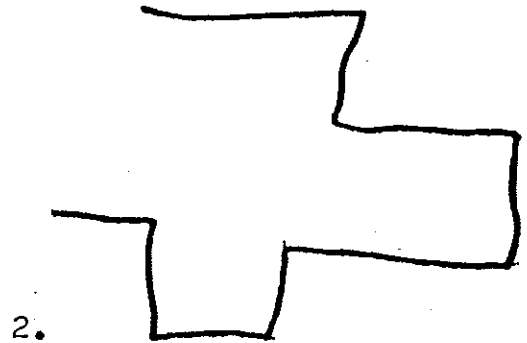
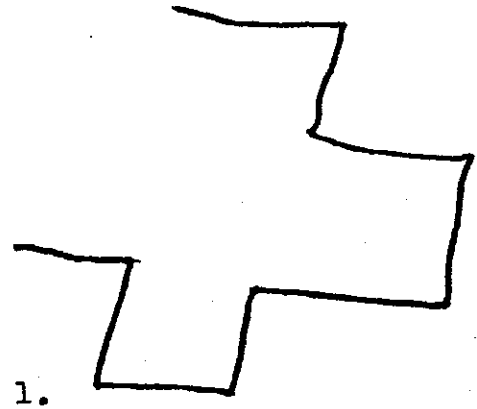
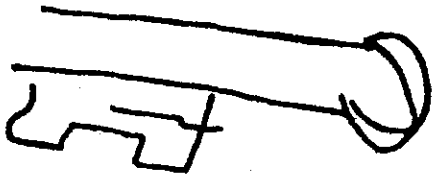


Square



85-27
27

58



Name C. H. Date Tested 4-30-56
 Hospital Veterans Ward 6-S Hospital No. _____
 Birthdate 6-9-25 Age 30 Education 12 Handedness Right
 Sex Male Occupation Farmer

Word Finding		W-B (Form I):	Category I II:	
Hemmon-Nelson	<u>78</u>	VIQ	<u>88</u>	1 0 2 1 3 1 4 2
Spokes A		PIQ	<u>117</u>	5 4 6 0 7 0
Spokes B		F-S IQ	<u>102</u>	Flicker - Cps
Trails A I II	<u>31"-10</u>	VWS	<u>36</u>	Dev
Trails B I II	<u>106"-2</u>	PWS	<u>59</u>	TPT I II III:
Trails Total	<u>137"-12</u>	Tot WS	<u>95</u>	RH <u>7.6</u> Time <u>15.4</u>
MMPI:		Inf	<u>11</u>	LH <u>5.4</u> Mem <u>10</u>
? <u>50</u> Pd <u>74</u>		Comp	<u>7</u>	BH <u>2.4</u> Loc <u>7</u>
L <u>70</u> Mf <u>61</u>		Digit Sp	<u>4</u>	Seashore Rhythm
F <u>68</u> Pa <u>73</u>		Arith	<u>3</u>	Raw Score <u>25</u>
K <u>64</u> Pt <u>71</u>		Simil	<u>11</u>	Speech Percept I II
Hs <u>93</u> Sc <u>88</u>		Vocab	<u>8</u>	Tapping: RH <u>60</u>
D <u>101</u> Ma <u>53</u>		P Arr	<u>14</u>	LH <u>56</u>
Hy <u>87</u>		P Comp	<u>12</u>	Time Sense - Memory
ABC: R <u>10</u> L <u>0</u>		Bl Des	<u>13</u>	Visual <u>21.0</u>
		Obj Assem	<u>11</u>	Impairment Index
		Digit Sym	<u>9</u>	<u>0.3</u>

Aphasic Symptoms: Auditory verbal dysgnosia, dysnomia, dyslexia, possible dysgraphia, and mild right finger dysgnosia.

Report of Neuropsychological Examination

This 30-year-old man obtained a Full-Scale Wechsler-Bellevue (Form I) IQ of 102 (Verbal IQ, 88; Performance IQ, 117). The aphasia examination indicated the following symptoms: auditory verbal dysgnosia, dysnomia, dyslexia, possible dysgraphia, and mild right finger agnosia. This difficulty with the symbolic communicational aspects of language account for the disparity in verbal and performance IQ-s. Although the subject obtained an Impairment Index of only 0.3, the W-B results and the dysphasic symptoms indicate definite brain damage which appears to be located maximally in the posterior part of the left temporal lobe and adjacent areas anteriorly. It would appear that our findings could be accounted for by postulating a vascular accident with rather focal effects and without much generalized involvement of the hemispheres. The Impairment Index of 0.3, together with excellent performances on certain tests, suggests that the immediate prognosis with respect to recovery of language functions is good. Personality measures indicate that this person is rather considerably disturbed affectively.

RMR

Comment

This patient performed very well on three of the four indicators we generally consider to be our most sensitive to the effects of brain damage (Impairment Index, Category Test, Localization component of the Tactual Performance Test). The fourth of these indicators (Part B of the Trails) was in the range characteristic of brain damage. However, the pronounced dysphasia shown by this patient indicated definitely that brain damage was present. (None of the

C. H. (Continued)

controls tested during the last seven years has been judged as having more than three dysphasic symptoms). Although one would be required to postulate damage in the left cerebral hemisphere because of the dysphasia, the relationship of performance between the two hands on both the Tactual Performance Test and Tapping Test did not suggest left hemisphere dysfunction. The only resolution of this finding was to postulate that the lesion was definitely focal in its effects and located some distance from the pre-central gyrus. Such an hypothesis would fit well with the pronounced receptive character of the patient's dysphasia. One rarely sees a distinct auditory verbal dysgnosia as a major component of dysphasia without involvement of the posterior left temporal area. The mild right finger dysgnosia implied some left parietal dysfunction, but we were led by the auditory verbal dysgnosia to believe that the left parietal dysfunction might be a function only of its adjacent location to a lesion in the posterior left temporal area. The patient drew a Greek cross somewhat poorly, but this isolated finding possibly implicating the right parietal area should not be depended upon in the presence of pronounced dysphasia.

The type of lesion was not difficult to infer. The test results required that we postulate a lesion with rather focal effects in the left hemisphere but also causing tissue damage sufficient to bring about a pronounced dysphasia. An intrinsic tumor could have caused the dysphasia but was out of the question in consideration of the Impairment Index and Category Test results. An extrinsic tumor might give the highly focal picture but would be entirely unlikely to have caused such serious dysphasia. The only remaining likely possibility was a cerebrovascular accident. We have never had a patient before with a cerebrovascular accident, causing pronounced dysphasia, do so well generally on the tests, but in most patients cerebrovascular accidents are probably a result of progressive cerebrovascular disease. The comment in the neuropsychological report on this patient to the effect that "...the immediate prognosis with respect to recovery of language functions is good" reflected our suspicion that progressive cerebrovascular disease was not present in this patient. As will be noted in the neurological summary, this patient suffered an intracerebral hemorrhage, probably as a result of hypertension developing from an ureteral pelvic junction obstruction due to an anomalous vessel.

Neurological and Neurosurgical Summary

Symptoms: 3-10-56 patient had sudden onset of headache, aphasia, and vomiting. No loss of consciousness. Lumbar Puncture done that day showed bloody CSF. He developed a right hemiparesis shortly after the onset. Blood pressure at time he was seen was 260/180. He gradually improved with bed rest.

Signs: Blood Pressure: 200/120.
Right-left disorientation.
Marked aphasia with dysnomia, dyslexia, dysgraphia, dyscalculia and finger agnosia.
Fundi showed marked hypertensive changes.
Right lower quadrantanopsia.
Right facial paresis, minimal.
Right hemiparesis, mild.
Right hemihypalgesia.

C. H. (Continued)

Handedness: Right.

Diagnostic CSF Protein, 45 mgm %.

Tests: Serology, negative.

EEG: Delta Grade II, left temporal-parietal.

X-rays: Skull films negative.


Treatment: A non-functioning kidney was found on the right. A nephrectomy was done on 5-22-56. Following this he did well. His blood pressure returned to normal levels and his aphasia improved markedly.

Diagnosis: Intracerebral hemorrhage.

Hypertension.

Ureteral pelvic junction obstruction due to anomalous vessel.

JK



C. H.

CLOCK

$$17 \times 3 = 51$$

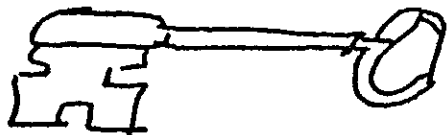
clock

Square

We shout

$$\begin{array}{r} 85 \\ 27 \\ \hline 58 \end{array}$$

$$\begin{array}{r} 39 \\ 56 \\ + 37 \\ \hline 132 \end{array}$$



Name W. L. Date Tested 10-1-58
 Hospital Veterans Ward 6-S Hospital No. _____
 Birthdate 10-16-16 Age 41 Education 16 Handedness Right
 Sex Male Occupation Vice-President of Bank

Word Finding	<u>42</u>	W-B (Form I):	Category I II:	
Hermon-Nelson	<u>135</u>	VIQ	<u>134</u>	1 0 2 1 3 2 <u>411</u>
Spokes A	<u>43"</u>	PIQ	<u>118</u>	5 7 6 0 7 1 <u>22</u>
Spokes B	<u>68"</u>	F-S IQ	<u>128</u>	Flicker - Cps
Trails A I II	<u>31"-10</u>	VWS	<u>75</u>	Dev
Trails B I II	<u>71"-6</u>	PWS	<u>55</u>	TPT I II III:
Trails Total	<u>102"-16</u>	Tot WS	<u>130</u>	RH <u>4.8</u> Time <u>17.2</u>
MMPI:		Inf	<u>12</u>	LH <u>6.6</u> Mem <u>6</u>
? <u>50</u>	Pd <u>55</u>	Comp	<u>18</u>	BH <u>5.9</u> Loc <u>0</u>
L <u>43</u>	Mf <u>53</u>	Digit Sp	<u>13</u>	Seashore Rhythm
F <u>46</u>	Pa <u>53</u>	Arith	<u>18</u>	Raw Score <u>28</u>
K <u>68</u>	Pt <u>58</u>	Simil	<u>14</u>	Speech Percept I II
Hs <u>72</u>	Sc <u>57</u>	Vocab	<u>16</u>	Tapping: RH <u>50</u> <u>50</u>
D <u>58</u>	Ma <u>43</u>	P Arr	<u>12</u>	LH <u>39</u>
Hy <u>71</u>		P Comp	<u>13</u>	Time Sense - Memory <u>142.6</u>
		Bl Des	<u>11</u>	Visual <u>133.0</u>
ABC: R <u>9</u> L <u>1</u>		Obj Assem	<u>12</u>	
		Digit Sym	<u>7</u>	Impairment Index <u>0.4*</u>

Aphasic Symptoms: No language deficit. Mild finger-tip number writing perceptual loss on both hands. Tendency toward suppression on right of bilateral simultaneous auditory stimulation.

Report of Neuropsychological Examination

This 41-year-old man obtained a Full-Scale Wechsler-Bellevue (Form I) IQ of 128 (Verbal IQ, 134; Performance IQ, 118). The tests of biological intelligence yielded an Impairment Index of 0.4 which is a marginal value with respect to the adequacy of organic brain functions. This patient's general level of performance is better than that of the average control subject, but certain aspects of relationships between test results is probably sufficient to indicate some impairment of brain functions. The patient's motor performances with his left hand were not as good as the performances with his right hand on either a test of motor speed (Tapping Test) or a more complex motor task (Tactual Performance Test). In addition, results on the performance part of the Wechsler Scale were considerably below those on the verbal part. These various findings are consistent in suggesting that the right hemisphere functions less well than the left. The patient showed a mild finger-tip number writing recognition loss on both hands. With bilateral simultaneous auditory stimulation, the patient failed to respond on his right side on two of four trials. This result would seem fairly definite in suggesting some damage in the left cerebral hemisphere. Thus, the total results suggest some fairly diffuse dysfunction in the right cerebral hemisphere but a definite indication of impaired function in the left cerebral hemisphere as well with the total level of performance being quite good. The Minnesota Multiphasic Personality Inventory suggests that this patient has mild to moderate neurotic-like difficulties. The entire picture is quite characteristic of that seen in relatively mild impairment associated with multiple sclerosis but our results should not be considered diagnostic for this disease.

W. L. (Continued)

Comment

The report describes the results in some detail for this patient. The picture is quite characteristic for patients with relatively mild impairment associated with multiple sclerosis. The patient performed quite well in general but, nevertheless, evidence of bilateral cerebral dysfunction was present. Even such a serious symptom as auditory suppression was present although this is usually seen in patients having intrinsic brain tumors or acute cerebrovascular accidents. The fact that the auditory suppression suggested damage of the left hemisphere but that the other tests generally implicated the right hemisphere was very helpful in reaching the diagnostic impression. This type of disparity, that may be associated with rather discrete lesions such as the plaques that occur in multiple sclerosis, is rarely seen in other conditions. The effects of multiple sclerosis and closed head injuries may be difficult to differentiate in a number of instances, but closed head injuries rarely give the discrete, focal signs that are often seen in multiple sclerosis.

Neurological and Neurosurgical Summary

Symptoms: In 1946 patient first noted weakness of left leg and foot. This has slowly progressed.

Signs: Bitemporal pallor.
Absent abdominal reflexes.
Weakness and atrophy of left lower extremity with foot drop.
Babinski positive on left, reflexes hyperactive, left.

Diagnostic Tests: X-rays: Skull films negative.

Diagnosis: Multiple Sclerosis.

Symptoms: Readmitted 9-12-58 to 10-3-58 because of increasing weakness now also affecting the upper extremities.

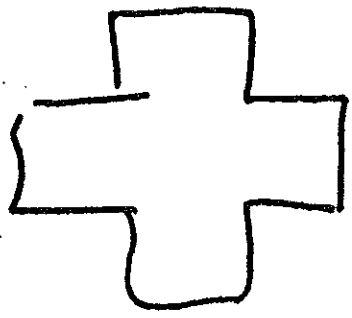

Signs: Bitemporal pallor.
Nystagmus.
Spastic paraparesis.
Adiokokinesis, left more than right.
Mild ataxia, left upper extremity.

Handedness: Right.

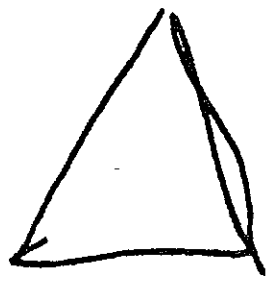
Treatment: Treated with steroids, improved slightly.

Diagnosis: Multiple Sclerosis.

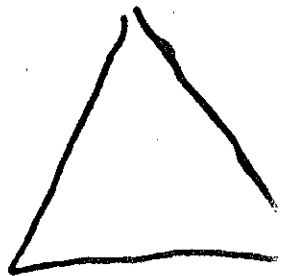
JK



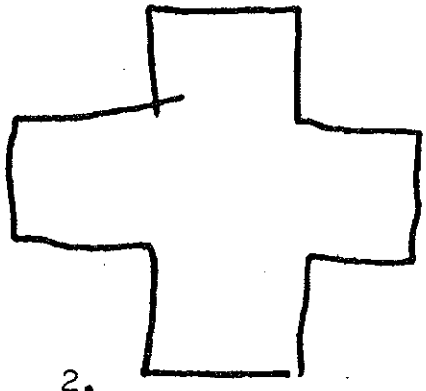

1.



1.



2.




2.

clock square

He shouted the warning

85 - 27 = 58 51



Name W. M. Date Tested 9-22-57
 Hospital Long Ward G Hospital No. _____
 Birthdate 1-28-13 Age 44 Education 14 Handedness Right
 Sex Male Occupation Sales Engineer

Word Finding	W-B (Form I):	Category I II:	
Herron-Nelson	VIQ <u>109</u>	1 0 2 0 3 21	<u>413</u>
Spokes A	PIQ <u>99</u>	5 22 6 12 7 4	<u>72</u>
Spokes B	F-S IQ <u>104</u>	Flicker - Cps	
Trails A I II <u>51"-7</u>	VWS <u>53</u>	Dev	
Trails B I II <u>183"-1</u>	PWS <u>39</u>	TPT I II III:	
Trails Total <u>234"-8</u>	Tot WS <u>92</u>	RH <u>5.4</u>	Time <u>23.3</u>
	Inf <u>9</u>	LH <u>10.7</u>	Mem <u>5</u>
MMPI:	Comp <u>15</u>	BH <u>7.2</u>	Loc <u>0</u>
? _____ Pd _____	Digit Sp <u>7</u>	Seashore Rhythm	<u>2</u>
L _____ Mf _____	Arith <u>9</u>	Raw Score <u>28</u>	
F _____ Pa _____	Simil <u>13</u>	Speech Percept I II	<u>12</u>
K _____ Pt _____	Vocab <u>15</u>	Tapping: RH <u>61</u>	<u>61</u>
Hs _____ Sc _____	P Arr <u>6</u>	LH <u>55</u>	
D _____ Ma _____	P Comp <u>9</u>	Time Sense - Memory	
Hy _____	Bl Des <u>7</u>	Visual	
ABC: R _____ L _____	Obj Assem <u>10</u>		
	Digit Sym <u>7</u>	Impairment Index	<u>0.7*</u>

Aphasic Symptoms: Spelling dyspraxia, mild right-left disorientation, finger dysgnosia (fingers 3,4, and 5 of left hand and finger 3 of right hand), construction dyspraxia.

Report of Neuropsychological Examination

This 44-year-old man obtained a Full-Scale Wechsler-Bellevue (Form I) IQ of 104 (Verbal IQ, 109; Performance IQ, 99). The tests of biological intelligence were not completely administered because of time limitations. The more important of these tests, however, were given. On seven of the ten tests the patient achieved an Impairment Index estimated to be 0.7, which places his performance in the range characteristic of impaired brain functions. This Impairment Index together with poor scores on the Category Test and the Trails Part B Test suggest very strongly that there is organic damage of the brain. The aphasia examination revealed several interesting findings. In testing for simultaneous bilateral visual stimulation, the patient failed to respond on his left side to either a single or bilateral stimulus. The patient showed no dystereognosis in either hand, and on the first testing showed no finger agnosia or fingertip number writing loss on either hand. When tested the next day, however, the patient was unable to identify fingers 3,4, and 5 on the left hand with fair consistency. In addition, he had difficulty identifying the third finger of his right hand when it was stimulated. When first asked to copy a Greek cross, he made quite a satisfactory drawing. Upon repetition of this procedure a day later, however, he rather clearly distorted the drawing. Taken together, these results rather consistently implicate the posterior part of the right hemisphere. On the Tactual Performance Test the subject required only 5.4 minutes with his right hand but on repeating the task with his left hand required 10.7 minutes. Nevertheless, his tapping speed with both right and left hands was quite fast and showed relatively little deviation from the expected relationship between hands. These deviations from normal performance on rather strictly motor tasks are probably not due to peripheral loss of function as judged from the results

W. H. (Continued)

on the aphasia examination as well as from certain other tests. While the results clearly implicate the posterior part of the right hemisphere and suggest structural damage in this area, the severity of the losses is not sufficient to support a conclusion of a rapidly growing intrinsic tumor. Several results suggest the possibility that the left hemisphere is not functioning quite as well as it might normally. The patient had great difficulty spelling even simple words although he claimed that he never had been able to spell well. In addition, he showed a mild right-left disorientation although this was not a severe disturbance. Finally the patient's finger agnosia for the third finger of the right hand suggests some loss of function in the left parietal area. Although the preponderance of our findings suggest structural damage in the posterior part of the right hemisphere, these mild indications of dysfunction in the left hemisphere are considerably more common with vascular disturbances rather than neoplastic growths. The best inference to be drawn from our results, in the absence of any other information, is probably that the lesion represents some type of vascular difficulty. Whether this represents a small thrombosis or early aneurysm would not be possible to say from our test results, but it would seem to be a type of pathological change that has not caused severe and widespread structural damage at the present time.

RMR

Comment

This patient had a posterior parietal-occipital lesion of the right hemisphere that in all probability was a metastatic melanoma. This lesion was demonstrated by angiography. Dr. Robert F. Heimbürger's notes for the Neuropsychology Laboratory, written at the time of the patient's discharge from the hospital, indicate that "there are possibly many more smaller metastases" that were not shown by angiography. Thus, the indications from the neuropsychological testing of bilateral cerebral involvement may not have been in error. Nevertheless, the bilateral indications were responsible (as indicated in the report) for our inference that brain dysfunction was on a vascular basis. Retrospectively, we should have been more impressed with the increasing symptoms from the first to the second day of testing and, in turn, thought along the lines of a type of lesion that would more likely be steadily progressive. (This case illustrates an important point with respect to interpretation of neuropsychological findings. The possibility of multiple metastatic carcinoma from a primary site other than the lung had occurred to me as the most likely possibility when first reviewing the test results, but this possibility did not occur to me at all a few days later when the report was dictated. In order to understand what the test results indicate about brain function and to translate this understanding into a diagnostic possibility, the interpreter must be sure to consider all of the possibly relevant diagnoses).

Neurological and Neurosurgical Summary

Symptoms: Patient had severe frontal headaches of increasing severity for 3 weeks. He has bumped into things on the left for several weeks.
Malignant melanoma removed, right scapula, December 1956.
Right axillary nodes, positive in March 1957.

W. M. (Continued)

Signs: Left homonymous hemianopsia.
Hypesthesia, right ulnar area.

Handedness: Right.


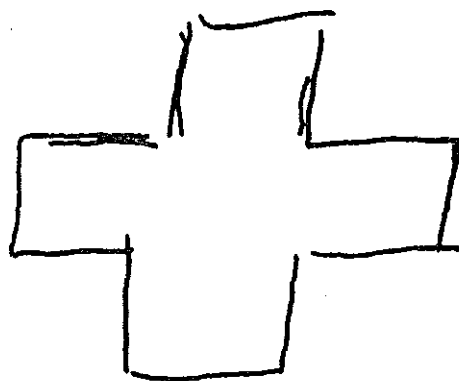

Diagnostic EEG: Delta Grade III, right parietal area.

Tests: X-ray: Metastatic lesion, upper left chest.
Angiogram: ? metastatic lesion, right posterior parietal-
occipital area.

Treatment: Headaches improved. Because of multiple lesions, the patient was discharged with no further treatment.

Diagnosis: Probable metastatic melanoma, right posterior parietal-occipital area.

JK




clock.

squair
square

he shouted the worning

$$85 - 27 = 58$$



REPEATED THE NEXT DAY

