

ECMO and steroids for Severe COVID-19 Respiratory Failure

Mark Caridi-Scheible, MD

Critical Care Medicine

Medical Director, Emory ECMO Program



Patient information

- 61 yo
- Female
- Hypertension, Type 2 Diabetes
- Obesity, BMI 35, below our average, some likely volume overload
- Relative baseline healthiness in line with our pre-established COVID ECMO criteria for age bracket
- All dates that follow are changed but relatively correspond



COVID-19 History of Present Illness

- Date symptoms began
- COVID-19 test: positive 8/9/20
- Presented to OSH 8/11/20 for worsening:
 - SOB
 - Cough
 - Fever
 - Headache
 - Flank pain and decreased urine output



Clinical Hospital Course

- Presenting AKI resolved with fluid, but now volume overloaded
- 8/21/20 - Intubated at OSH after failure of Airvo & BiPAP with hypercarbia and hypoxia
- Progressively worsening hypoxia and hypercarbia despite lung protective ventilation, high peep, paralysis and proning
- Intubation day 3 - Saturations 80-85% despite FiO₂ 100%, PEEP +16
 - Unable to go higher due to inability to ventilate (PCO₂ 80-100)
 - Acidotic, but lactate was normal and kidneys perfusing
- Called by OSH for ECMO referral



ECMO Candidacy

- Met our criteria:
 - For age 60-70, minor co-morbidities and no other organ damage
 - Rapidly progressive hypoxic and/or hypercarbic failure despite:
 - Vent optimization, paralysis, proning
 - Inability of facility to:
 - Use more advanced vent modalities
 - Additional therapy (in this case, inhaled epoprostenol or nitric oxide)
 - Inability to transfer safely to higher level of care
 - Less than 7 days of intubation + BiPAP + Airvo
 - Beyond this VILI/SILI already inducing fibrosis
 - Potentially reversible process (COVID pneumonia)



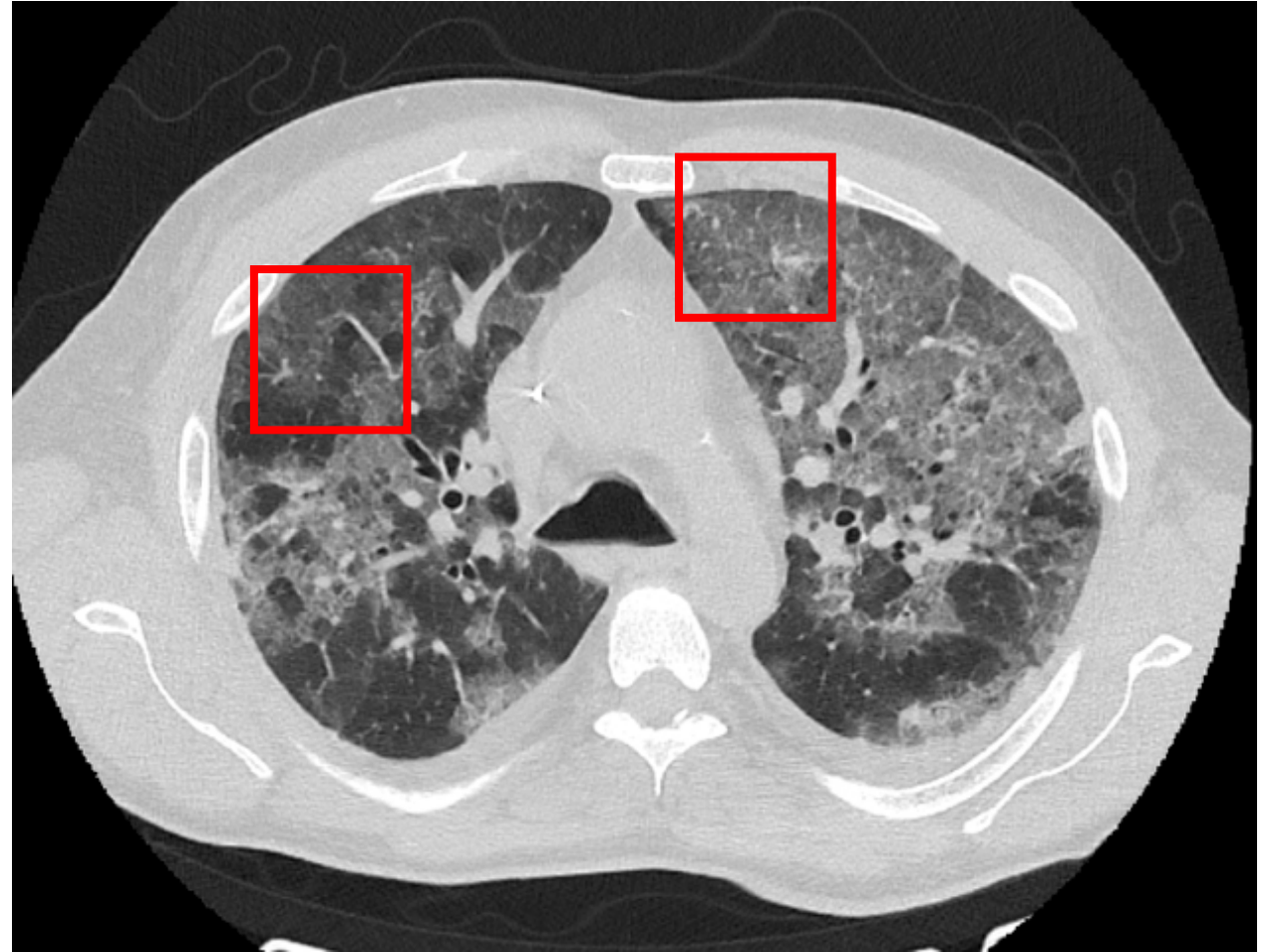
ECMO Initiation

- 8/23/20 - Team sent to OSH for remote cannulation
- Saturations on arrival (supine) 75%-79% and tachycardic
- 25 Fr Right femoral multistage drainage cannula
- 22 Fr Right internal jugular EOPA reinfusion cannula
- Initial flows 4.0 LPM
- Initial sweep 4 LPM, titrated to 9 LPM to achieve $PCO_2 < 55$
- SpO₂ now 90's, tachycardia resolving
 - Pressors initiated 2/2 reduced sympathetic drive
- 3 days 1mg/kg/day x3 days then rapid taper over 4 days



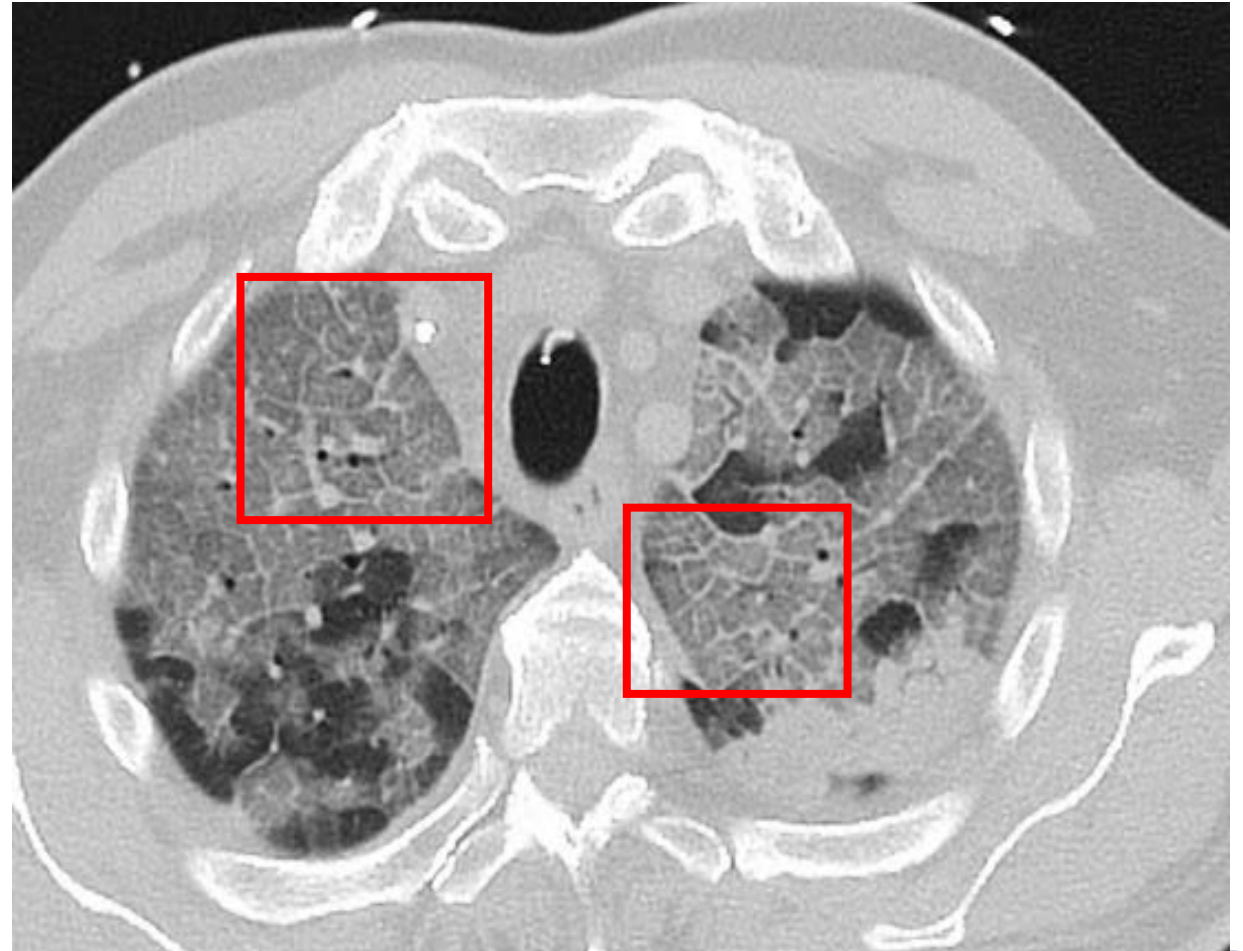
Radiology Lesson

- Outrageously simplified
- Ground glass
 - Inflammation
 - Infiltrates
 - Edema
 - Partially collapsed alveoli
- Generally reversible



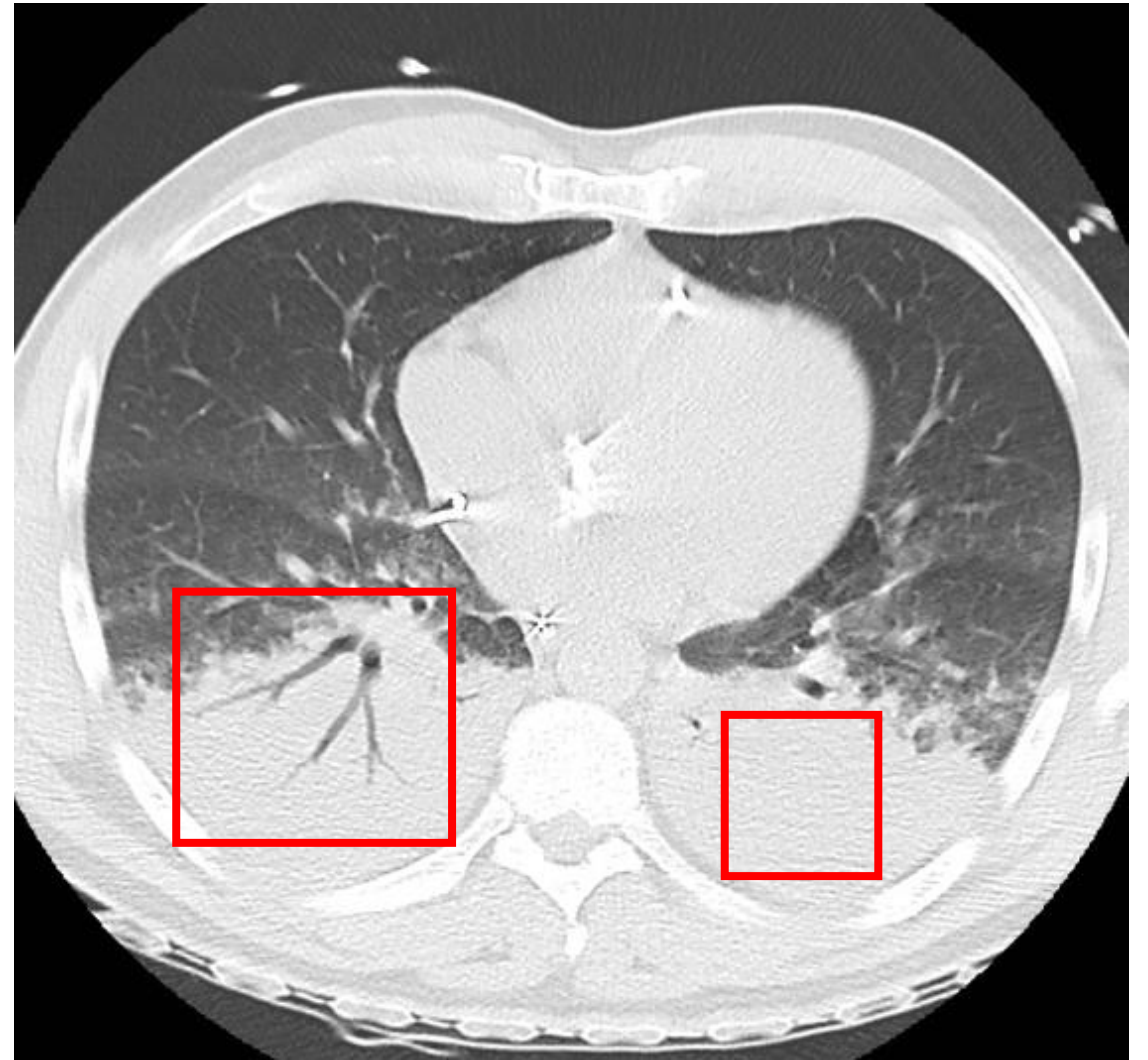
Radiology Lesson

- Crazy paving
 - Areas of ground glass surround by white borders, appearance of flagstone paving
 - Inflamed interlobular (groups of air sacs) septation membranes
 - Generally inflammatory process
 - Generally reversible



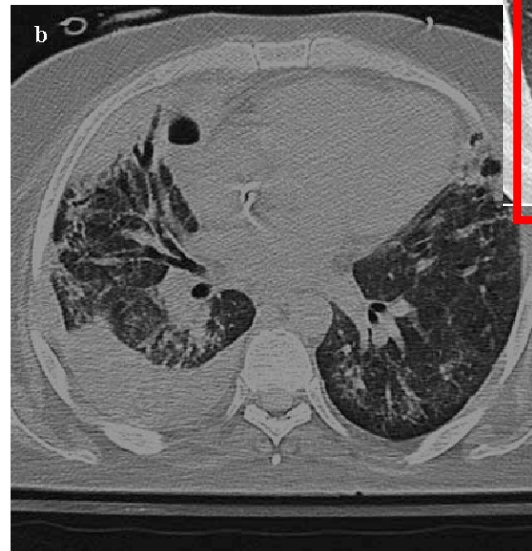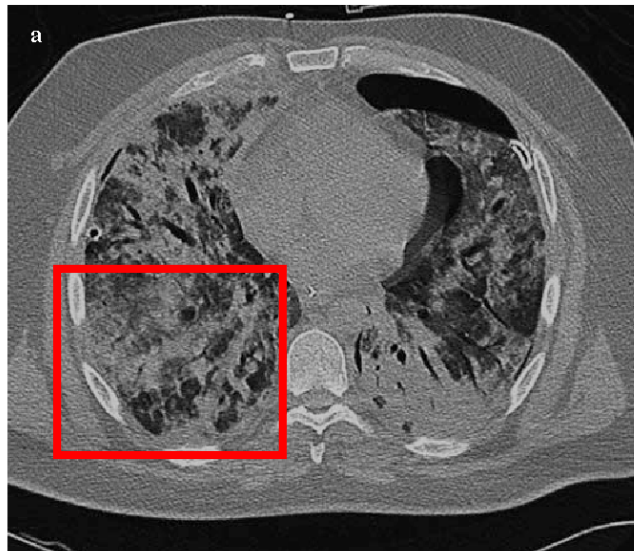
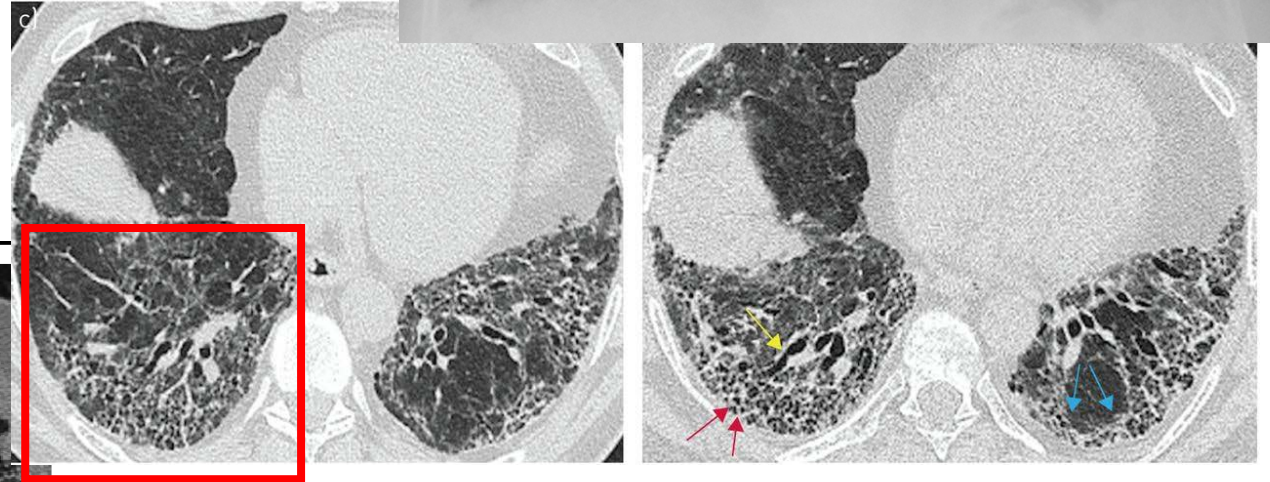
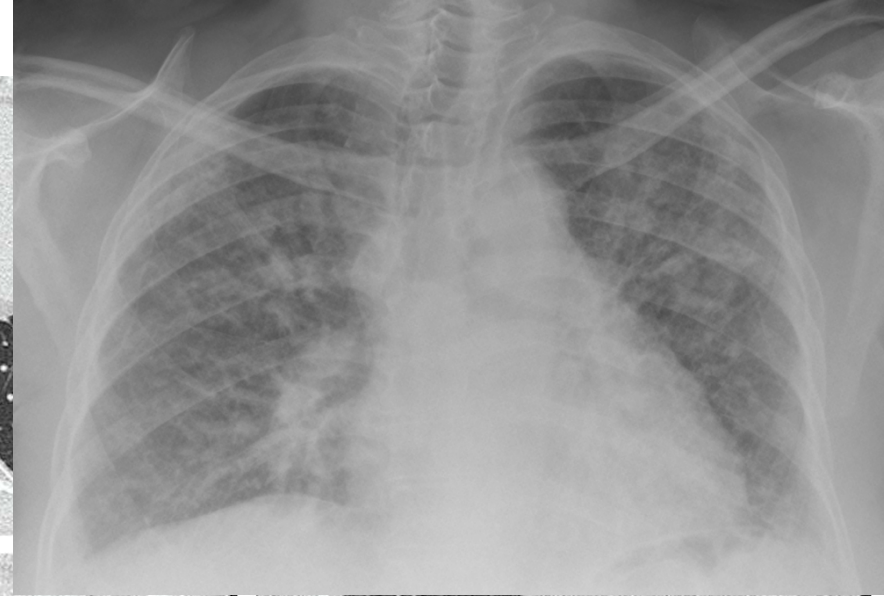
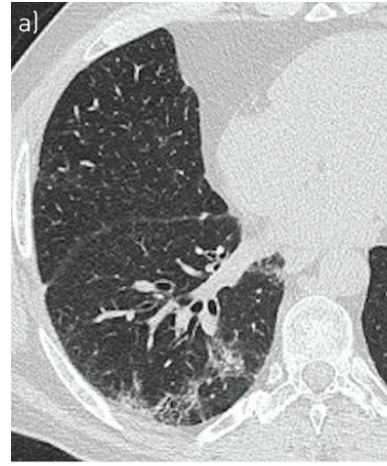Radiology Lesson

- Consolidation
 - Completely collapsed alveoli
 - Due to:
 - Inflammation
 - Infiltration (debris, fluid, pus)
 - Compression
 - Airway obstruction (e.g. mucous)
 - Airway collapse
 - Generally reversible



Radiology Lesson

- Fibrosis
 - Patent, enlarged airspaces surrounded by thick white scar
 - Traction bronchiectasis
 - Lung retraction
 - Generally not reversible



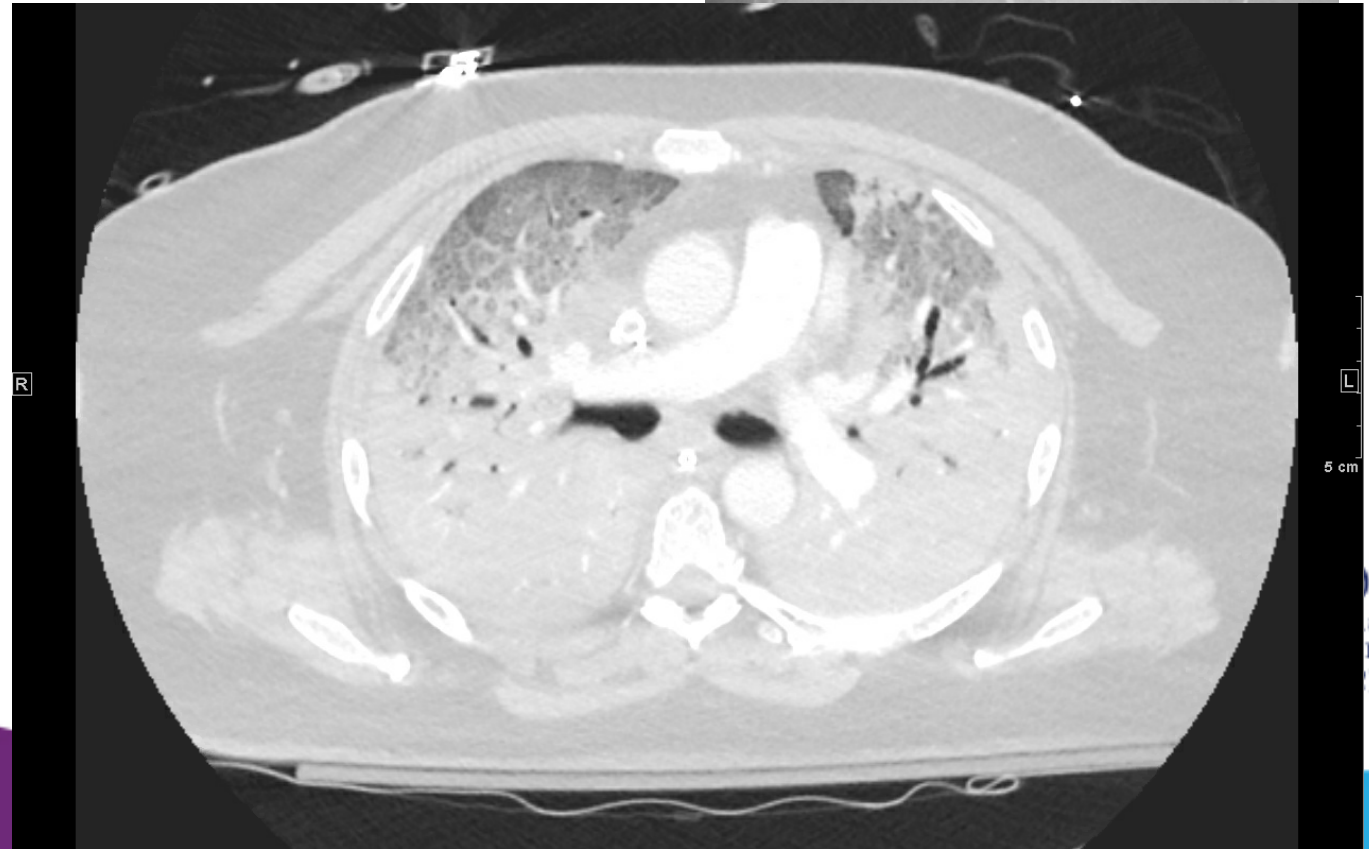
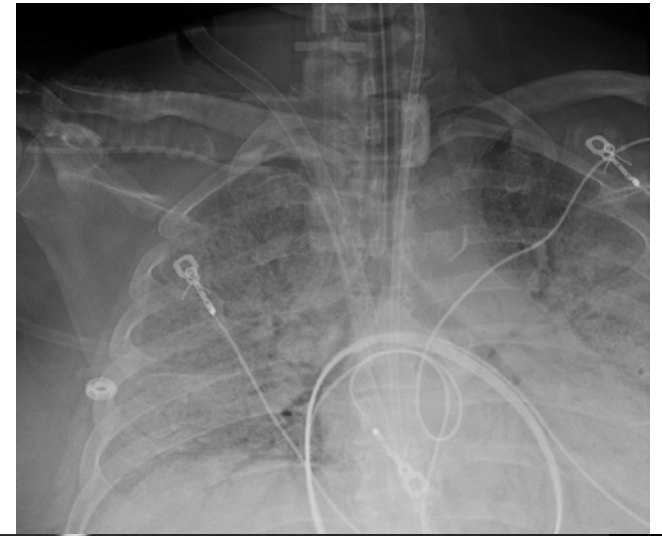
ECMO Course

- Complications consistent with many COVID runs
 - Small PE
 - Bleeding
 - Flow insufficiency, high O2 demand
 - Failed attempt secondary drainage cannula
 - Encephalopathy, high sedation requirements
 - Volume management
 - Diuresed with drip but difficult to get significantly negative daily due to high obligate intakes
 - Nosocomial infections
 - Fungemia, candida
 - Pseudomonas pneumonia, cephalosporin resistant
 - Prolonged duration



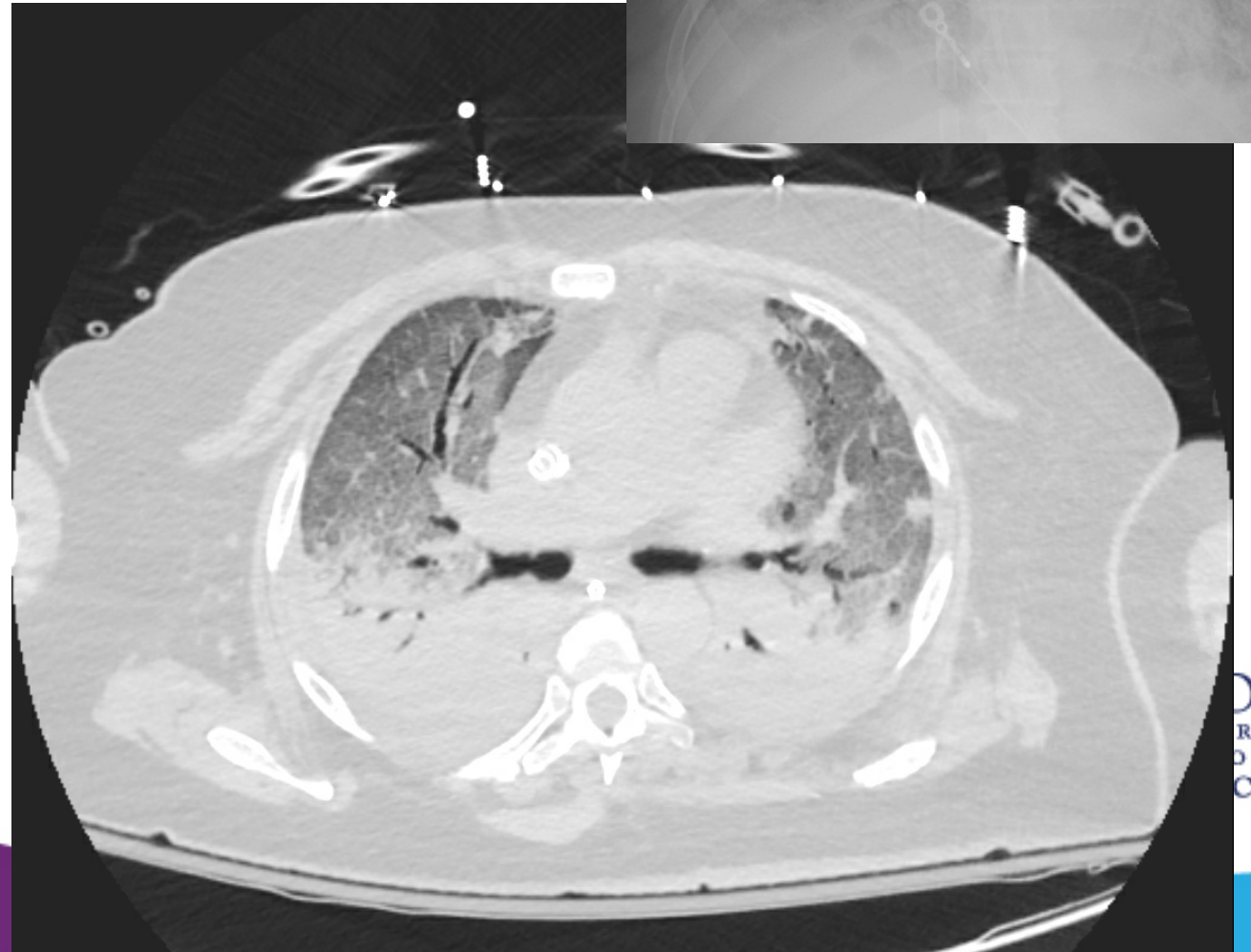
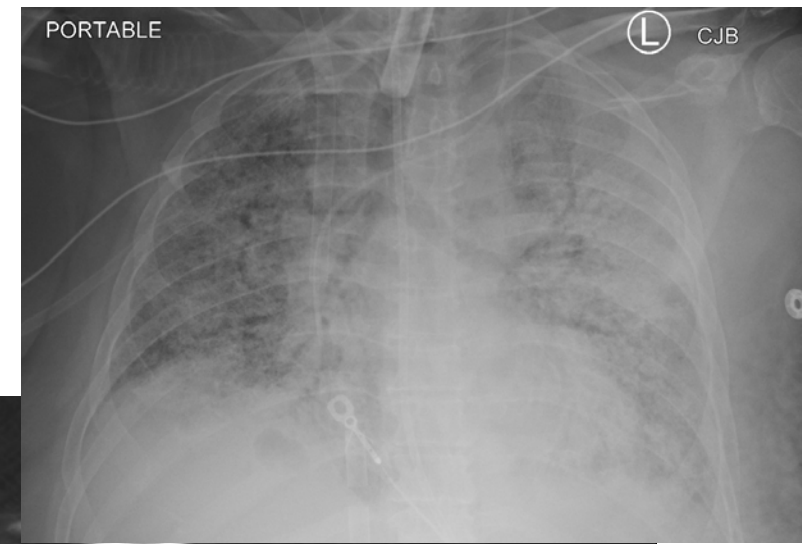
Results of treatment

- 8/24/20 Baseline scans
 - Ground glass
 - Crazy paving
 - Dependent consolidation
- CXR gives poor impression



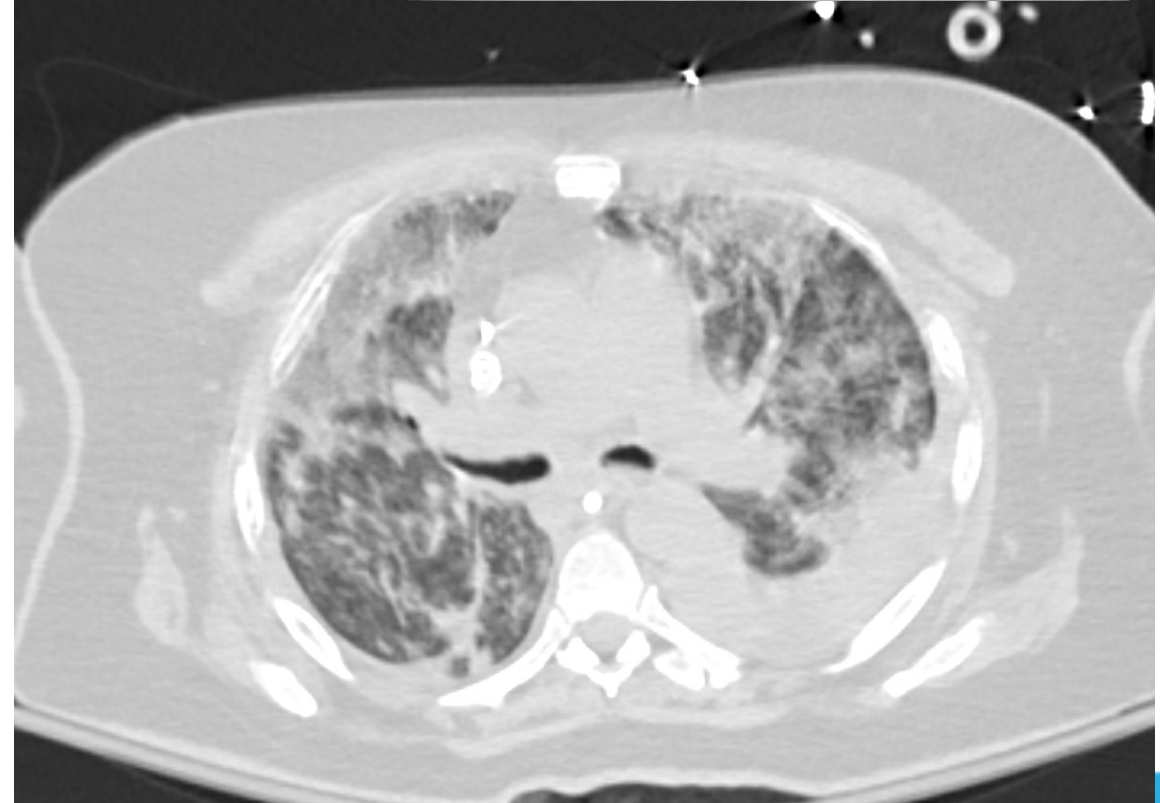
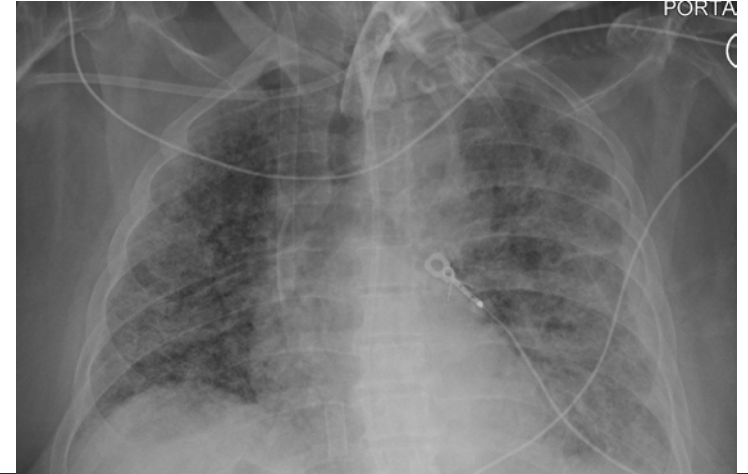Results of treatment

- 9/15/20 (3 week) scans
 - No clinical improvement
 - Slight improvement of consolidation on CT
 - Same diffuse inflammation
 - No evidence of fibrosis
- Decision to pulse steroid
 - 2mg/kg per day x 3 days
 - Then 7 day taper



Results of treatment

- 9/22/20 (4 week) scans
 - Marked clinical improvement (flows and sweep down)
 - Markedly improved aeration (and corresponding vent volumes)
 - Improvement in ground glass inflammation
 - In retrospect, some areas of increased infiltrate (turned out to have developing bacterial pneumonia)
 - Again, CXR doesn't tell story well



Results of treatment

- Improvement stalled 2 weeks later
 - Improved again after treating resistant pseudomonas
- Septic shock also in same time-frame
 - Responded to micafungin, switched to fluconazole later
- Transitioned to Avalon cannula (dual-lumen cannula) and circuit changed (9/26/20)
- Weaned from sedation
 - Helped with spontaneous breathing and improved recruitment



Results of treatment

- 9/30/21 - Decannulated
- 10/11/21 – Discharge to LTAC
 - 24 hours trach collar



Conclusions

- All prolonged respiratory failure is not necessarily fibrosis
 - CT can help guide therapy
 - CXR not sensitive enough, particularly to non-radiologists
- COVID is a steroid responsive disease
 - In this case, can't say for sure if was going to get better anyway
- ECMO in appropriate candidates can avoid further damage to lungs from VILI to allow treatment of underlying inflammation
 - Steroids, antimicrobials, * time *
 - Or bridge to transplant
- VV-ECMO for COVID challenging and atypical
 - 6-8 weeks not unusual (up to 2-3 months)

