

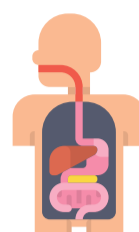


MANAGEMENT OF SEVERE ACUTE AND NECROTIZING PANCREATITIS

PATHOPHYSIOLOGY

Severe pancreatitis is persistent organ failure with local complications per Revised Atlanta Criteria

- Develops in 20% of acute pancreatitis (AP)
- 38% of severe pancreatitis develop organ failure in 1st week
- 42% mortality in 1st week
- 5-10% of AP develop pancreatic necrosis




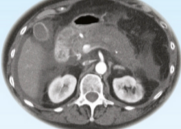

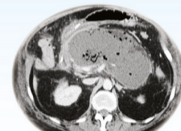
Acute inflammation + release of proteolytic enzymes → auto-digestion of pancreas → formation of (peri)-pancreatic necrosis

DIAGNOSIS

4 types of local complications

Contrast enhanced CT, best at >72 hours



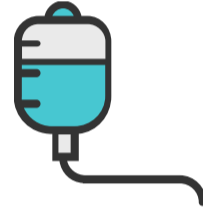
	Interstitial edematous pancreatitis	Necrotizing pancreatitis
< 4 weeks	Acute (peri)pancreatic fluid collection Homogenous fluid adjacent to pancreas without a recognizable wall 	Acute necrotic collection Intra and/or extra pancreatic necrotic collection without a well-defined wall 
≥ 4 weeks	Pancreatic pseudocyst An encapsulated, well-defined, usually extrapancreatic fluid collection with minimal solids 	Walled off necrosis Intra and/or extra pancreatic necrotic collection with a well-defined wall 

MANAGEMENT

- Early treatment with fluid resuscitation, pain control, and total enteric feeding
- Multidisciplinary approach with GI, surgery, IR, critical care, ID, and nutrition

Deterioration < 10-14 days is typically due to SIRS from sterile necrosis

Deterioration > 14 days is more likely from infected necrosis



Indication for intervention

- Clinical suspicion of, or documented necrotizing pancreatitis with clinical deterioration
- Ongoing organ failure, in absence of infected necrotizing pancreatitis
- In sterile necrotizing pancreatitis, if a) gastric, intestinal, or biliary obstruction via mass effect, b) persistent symptoms, c) disconnected pancreatic duct



Timing of intervention

- Should be avoided in early, acute period (1st two weeks), which is associated with greater morbidity and mortality
- Delaying intervention for 3-4 weeks to allow liquefaction and encapsulation of necrotic collection is best
- Exceptions include abdominal compartment syndrome, perforation of hollow viscus, severe hemorrhage, and ischemic bowel

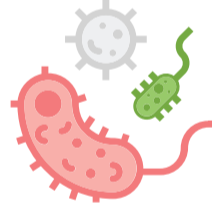
INFECTED NECROSIS

Background

- Typically late complication, >2 weeks after disease onset, 2/2 gut translocation
- Infected necrosis has high mortality (30%)
- No role for prophylactic antibiotics

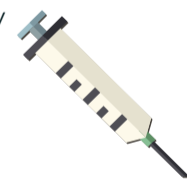
When to suspect?

- Presence of gas on CT (occurs only in about half of infected necrosis)
- Fevers, bacteremia, worsening leukocytosis
- Clinical deterioration in absence of other explanations



Should I sample?

- FNA if presence of clinical deterioration and if CT inconclusive for infected necrosis
- False negative in 12-25% of cases
- Aids with de-escalating empiric broad-spectrum antibiotics to targeted therapy
- < 1% chance of introducing infection



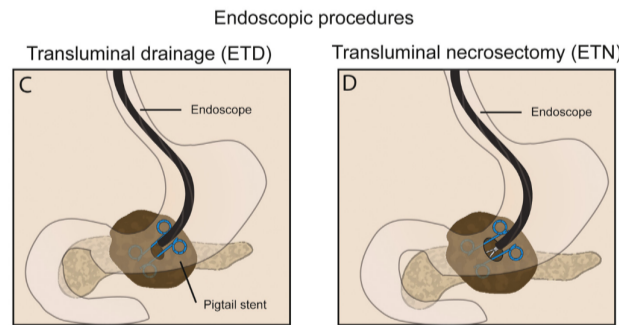
Which antibiotics?

- Initiate IV antibiotics that penetrate necrotic pancreatic tissue (carbapenems, quinolones, metronidazole, 3rd generation cephalosporin)

FURTHER INTERVENTIONS

Endoscopic Transluminal Drainage/Necrosectomy

- EUS to visualize and puncture collections & placement of stent transgastrically (cystgastrostomy) or transduodenally (cystduodenostomy)
- If necessary, followed with mechanical debridement with endoscopic necrosectomy
- ERCP with transpapillary stent placement for subacute drainage of symptomatic collection (less ideal for infectious which require faster drainage)



Percutaneous Catheter Drainage

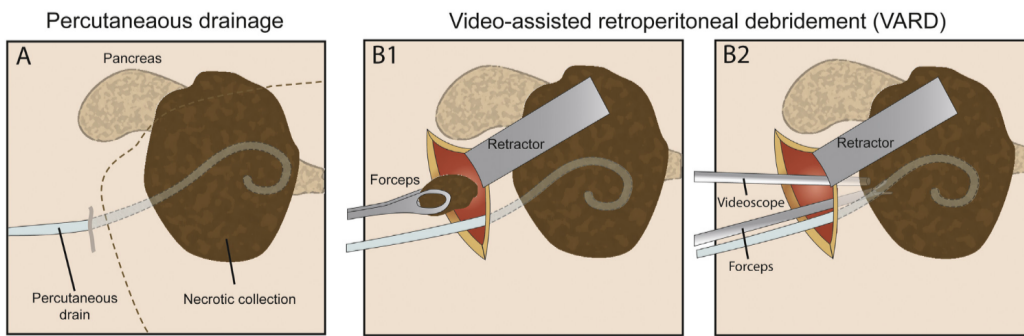
- Placement of single or multiple catheters, serially upsized, irrigated, and repositioned
- Source control for patients too sick for endoscopic transmural drainage
- Consider in < 2-4 weeks without mature walled off collection who are failing conservative management
- Consider when necrosis extends into paracolic gutters or pelvic space
- Can be done alone, or in combo with other interventions
- ↑ risk of pancreaticocutaneous fistula formation



Surgical Approaches

- Consider operative debridement in infected or sterile pancreatic necrosis with persistent organ dysfunction
- Minimally invasive options: Video-assisted retroperitoneal debridement (VARD), laparoscopic and open transgastric debridement
- VARD best for central distribution of necrosis extending into L paracolic gutter; Transgastric debridement best for centrally located necrosis

Surgical procedures



Step-Up Therapy

- Percutaneous drainage, followed by endoscopic drainage/debridement or VARD if necrosis does not resolve



@EmoryGastroHep

By Andrew Yu MD, Anudeep Neelam MD